RØNTGEN THORAX

Sven Weum

Røntgenavdelingen
Universitetssykehuset Nord-Norge

Røntgen thorax

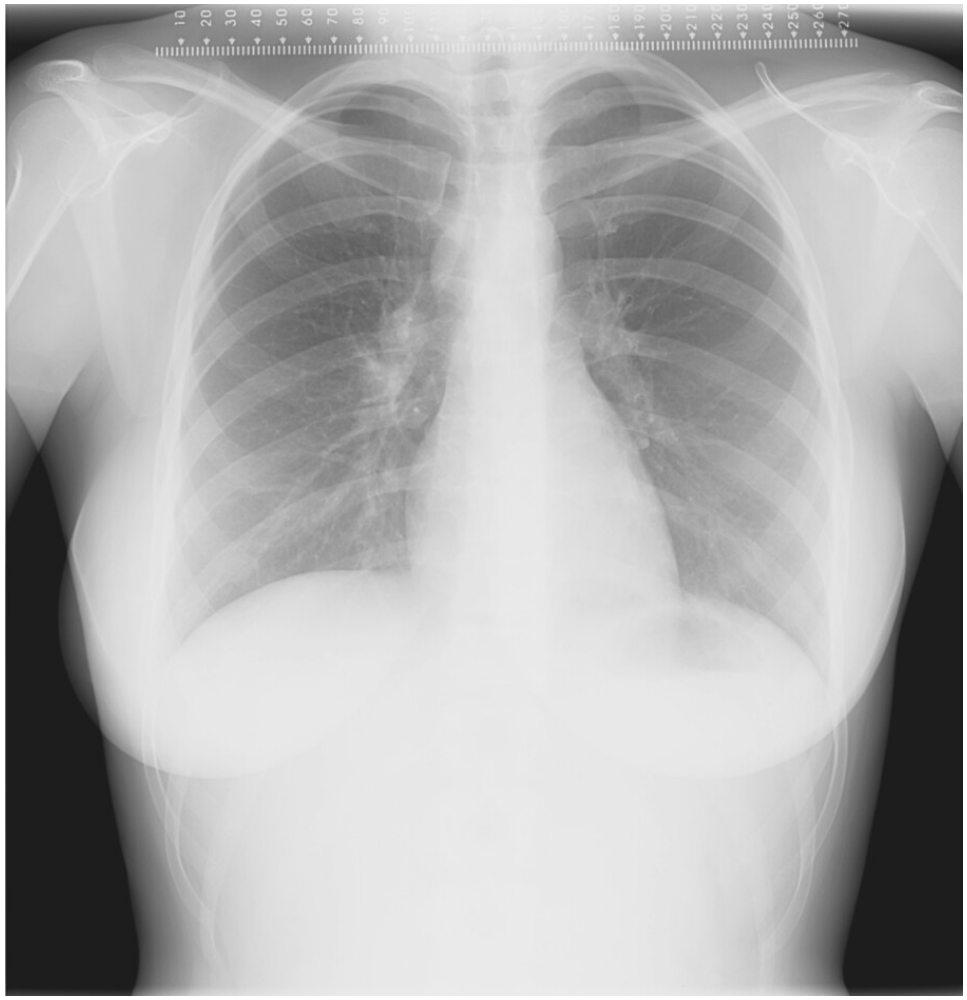

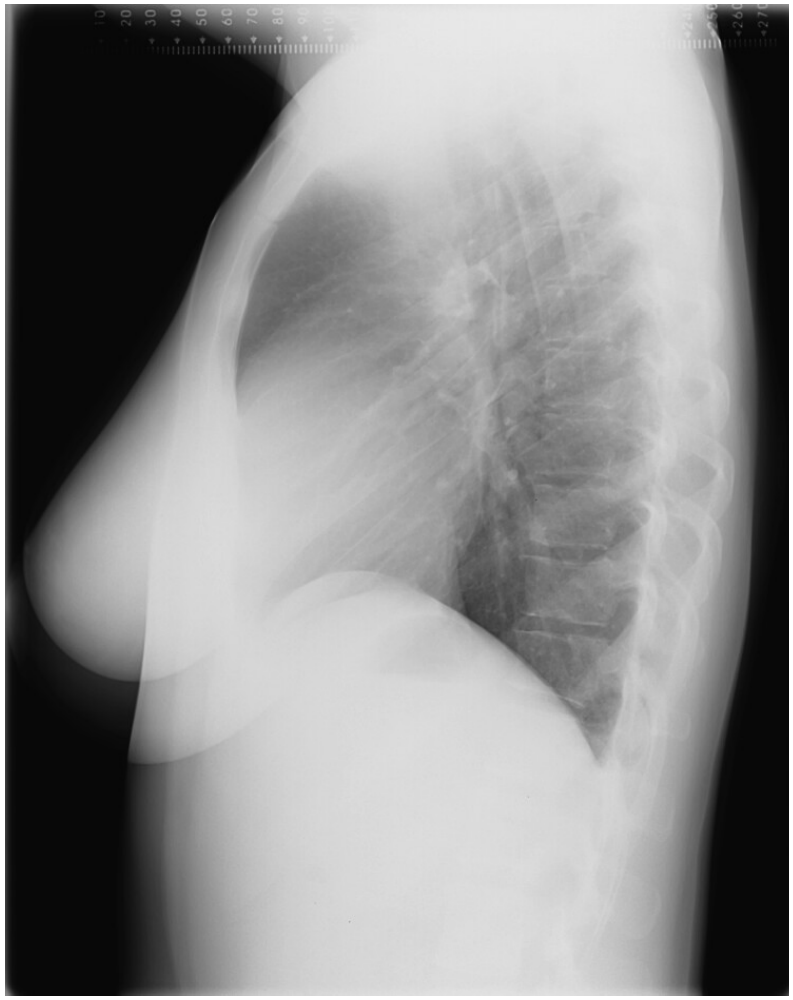



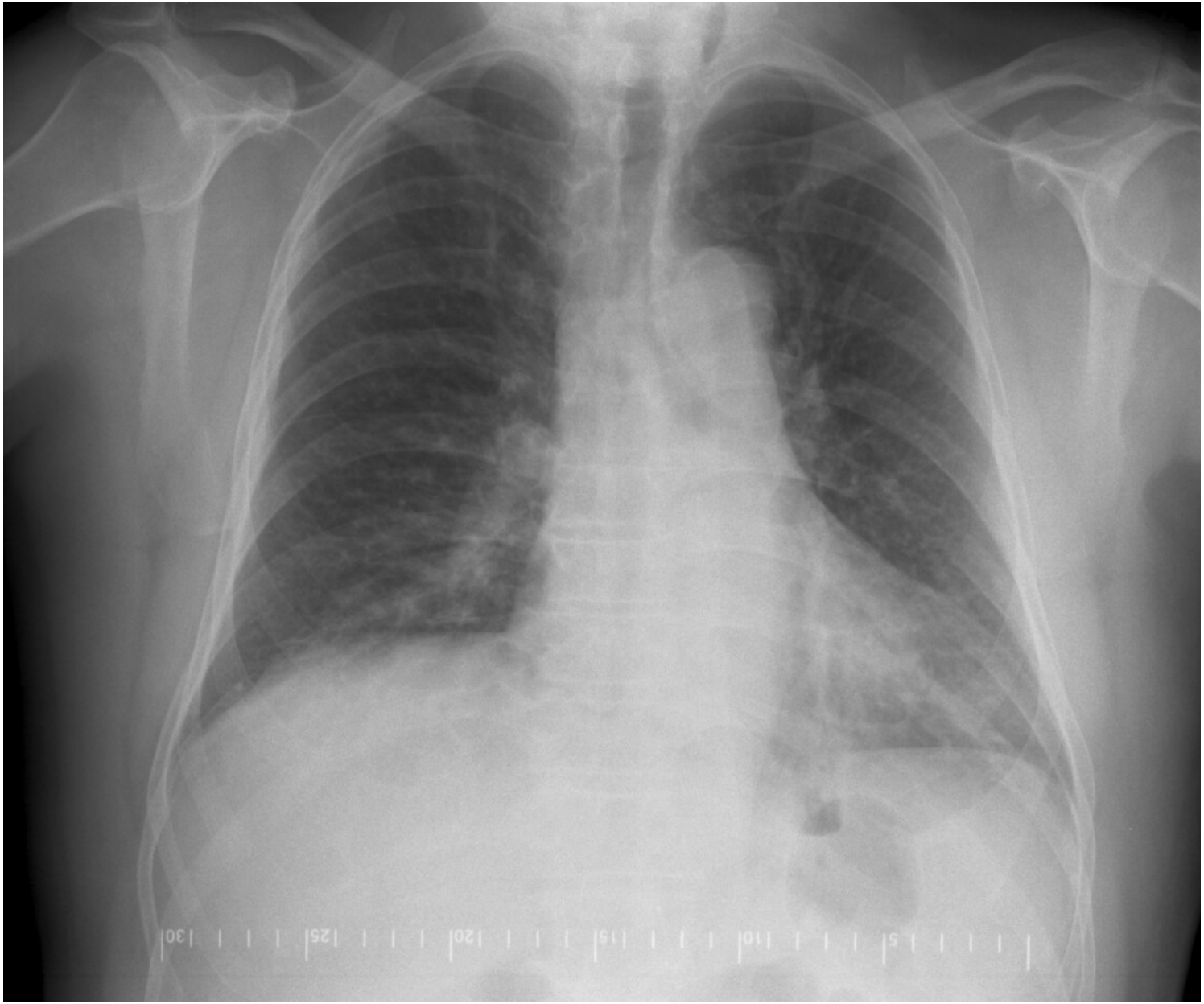

Buckybilde

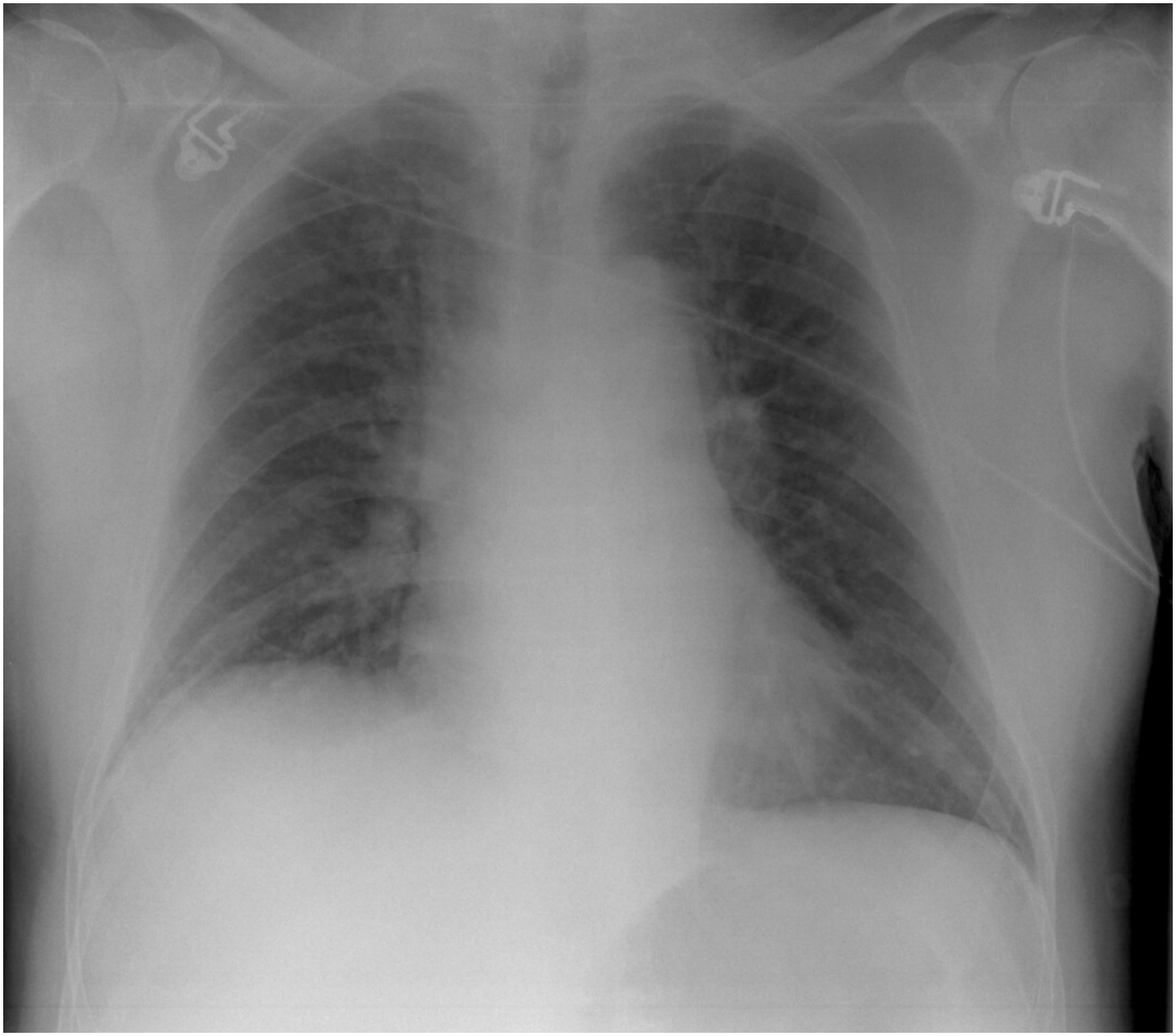

Sengebilde

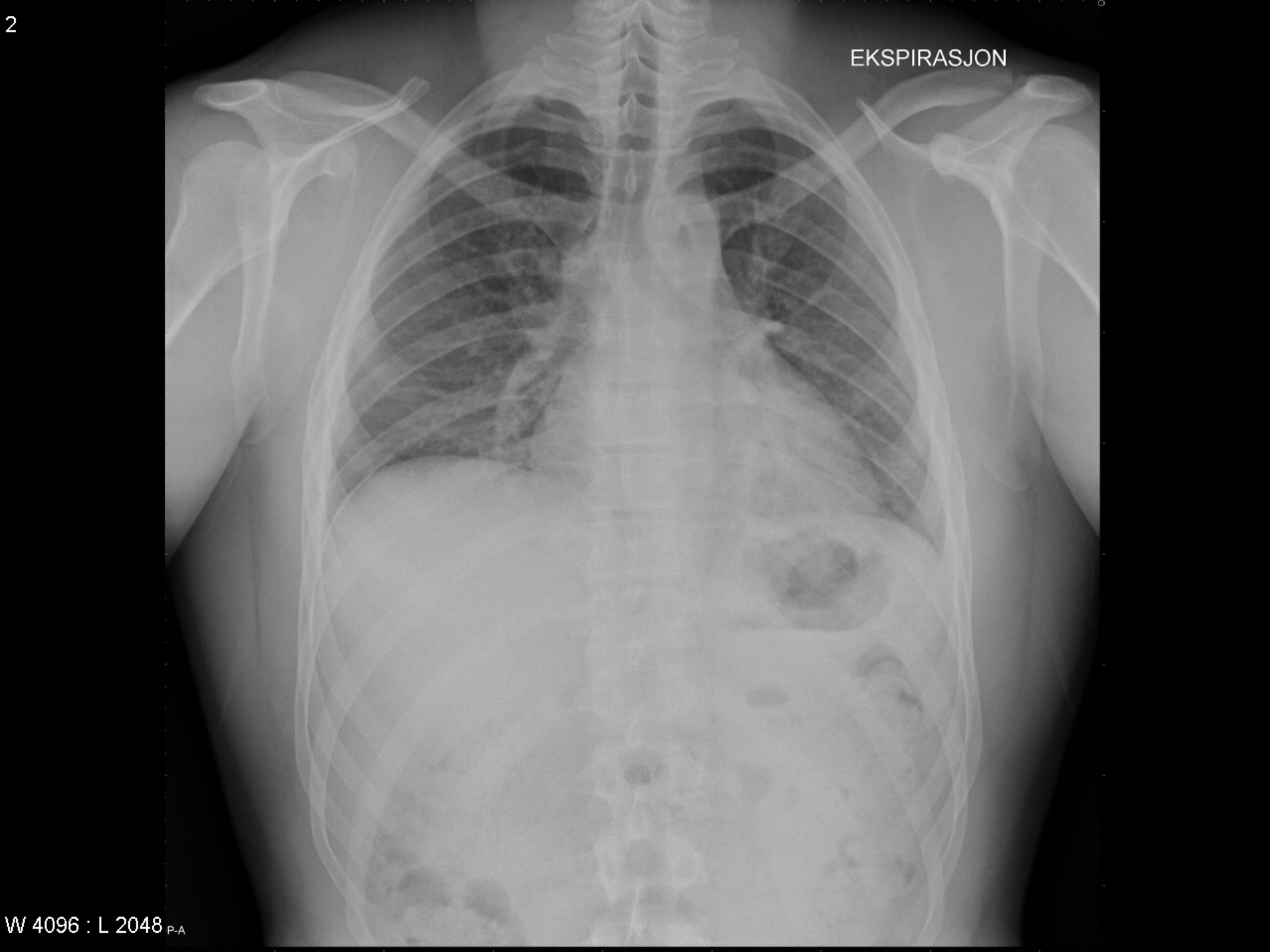
2
EKSPIRASJON
W 4096 : L 2048
P-A

Buckybilder

- Pasienten stående
- Tas PA (front mot detektorpanelet)
- Luft stiger opp (pneumothorax)
- Væske vil gå ned (pleuravæske)
- Både front- og sidebilde
- Generelt mye bedre kvalitet

Sengebilde

- Tas AP i stedet for PA
- Hjertet ser større ut
- Kar i øvre del av lungene ser videre ut
- Luft vil legge seg fortil (pneumothorax)
- Væske vil legge seg baktil (pleuravæske)
- Generelt dårligere bilder

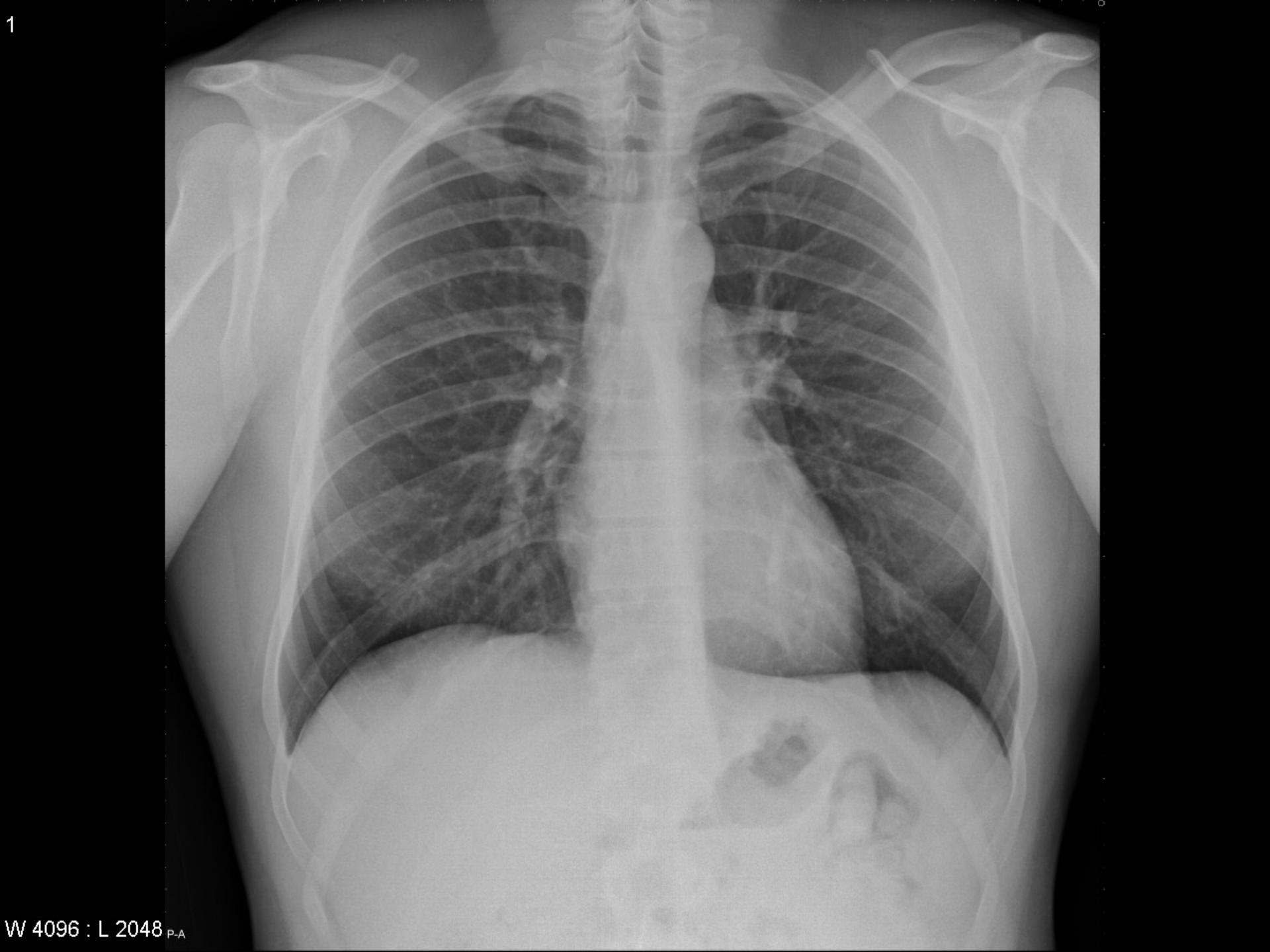
1
W 4096 : L 2048
P-A

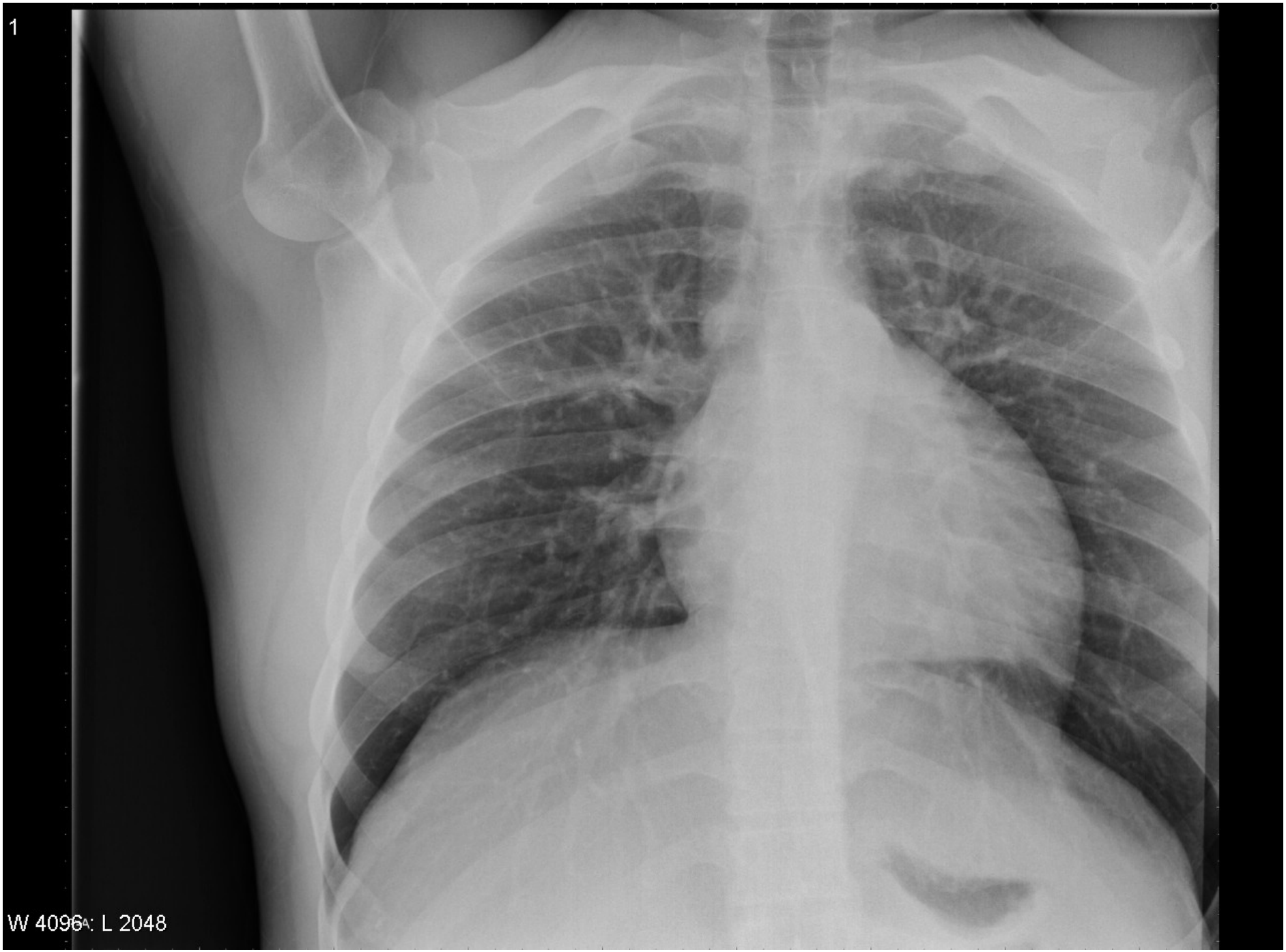
1
W 4096 A: L 2048

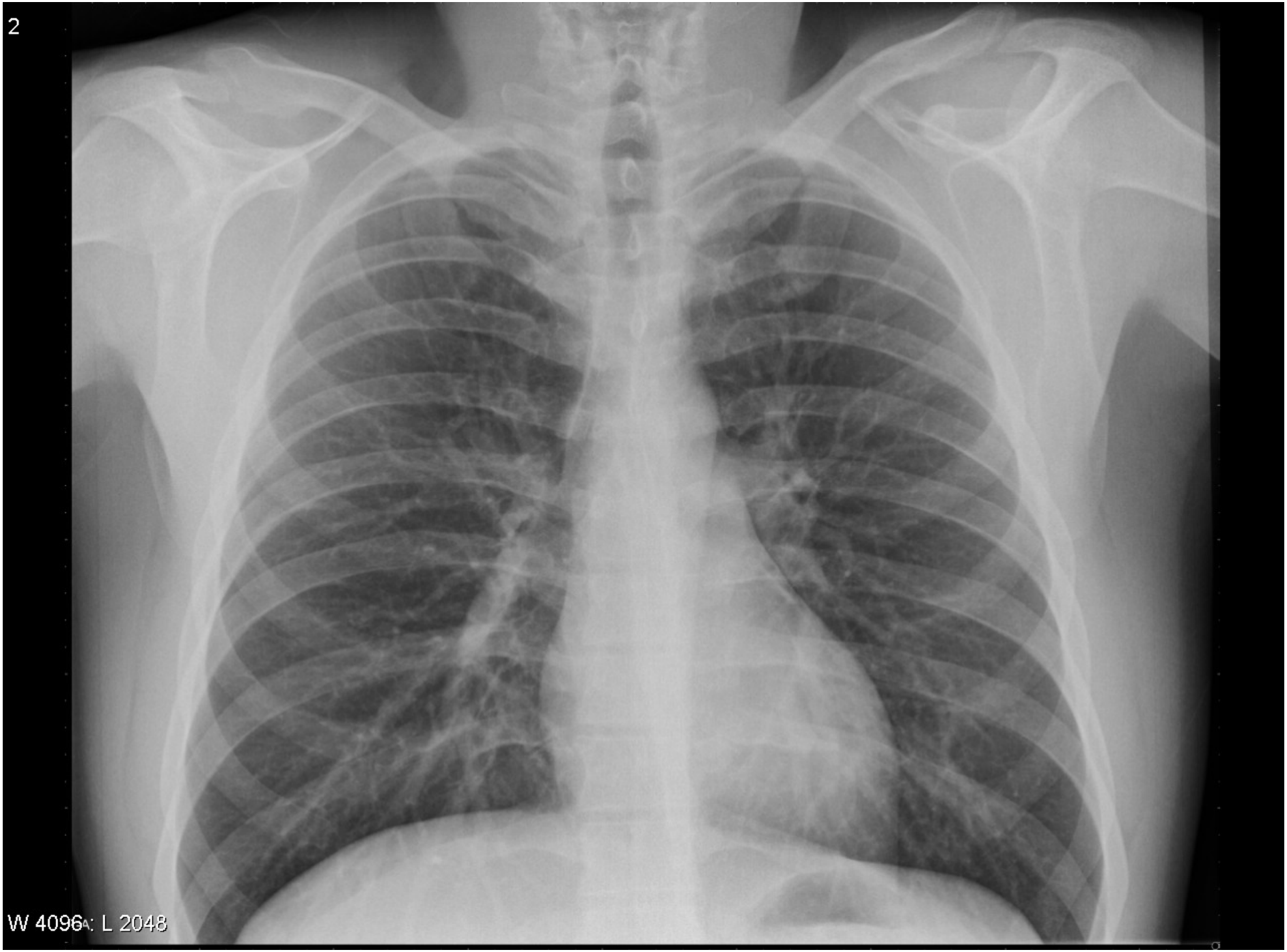
2
W 4096 A: L 2048


wallis
DRESS TO KILL

Wallis
DRESS TO KILL

DANGER
wallis
DRESS TO KILL

Pulp Fiction
wallis
DRESS TO KILL

Røntgen thorax

- Fortetninger (lysere)
- Oppklaringer (mørkere)
- Forskyvning av anatomiske strukturer

Fortetninger

- Stor absorpsjon røntgenfotoner
- Flere atomer eller høyere atomnummer
- Beinvev inneholder Ca^{20}
- Færre røntgenfotoner når fram til detektorpanelet eller filmen
- Mindre svertning på bildet

Oppklaringer

- Mindre absorpsjon av røntgenfotoner
- Færre atomer eller lavere atomnummer
- Bløtdeler inneholder H^1, C^6 og O^8
- Flere røntgenfotoner når fram til detektorpanelet eller filmen
- Økt svertning på bildet

Forskyvning

- Vi må kjenne normalanatomien
- Endringer i organenes plassering
- Ekspansjon
- Retraksjon

"Nurse, get on the internet, go to SURGERY.COM, scroll down and click on the 'Are you totally lost?' icon."

BLØTDELER

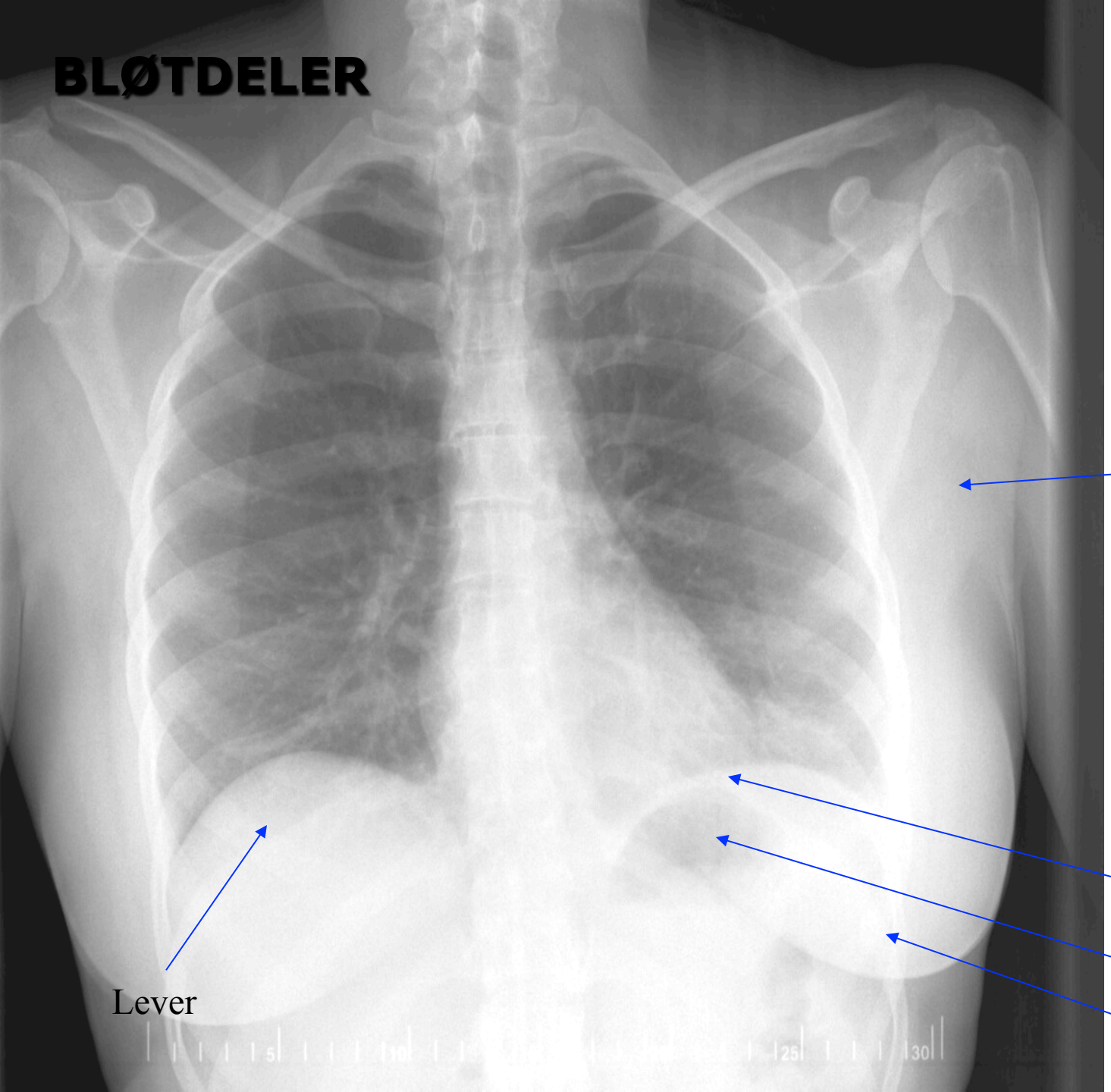
Subcutis og muskulatur
Diafragmakuppel
Ventrikkel
Mamma
Lever

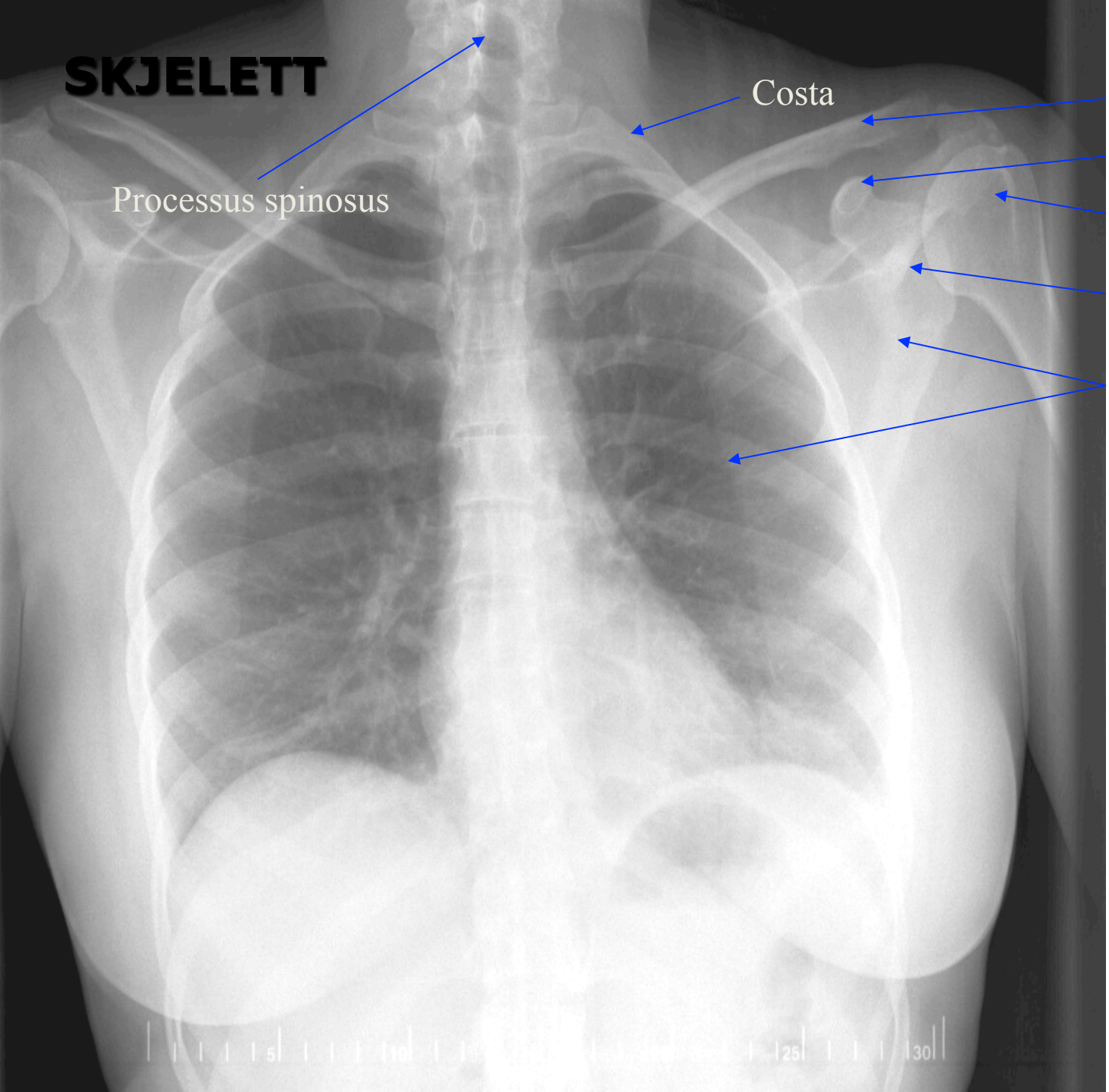
SKJELETT
Processus spinosus
Costa
Clavicula
Processus coracoideus
Caput humeri
Cavitas glenoidale
Scapula

LUNGER OG MEDIASTINUM

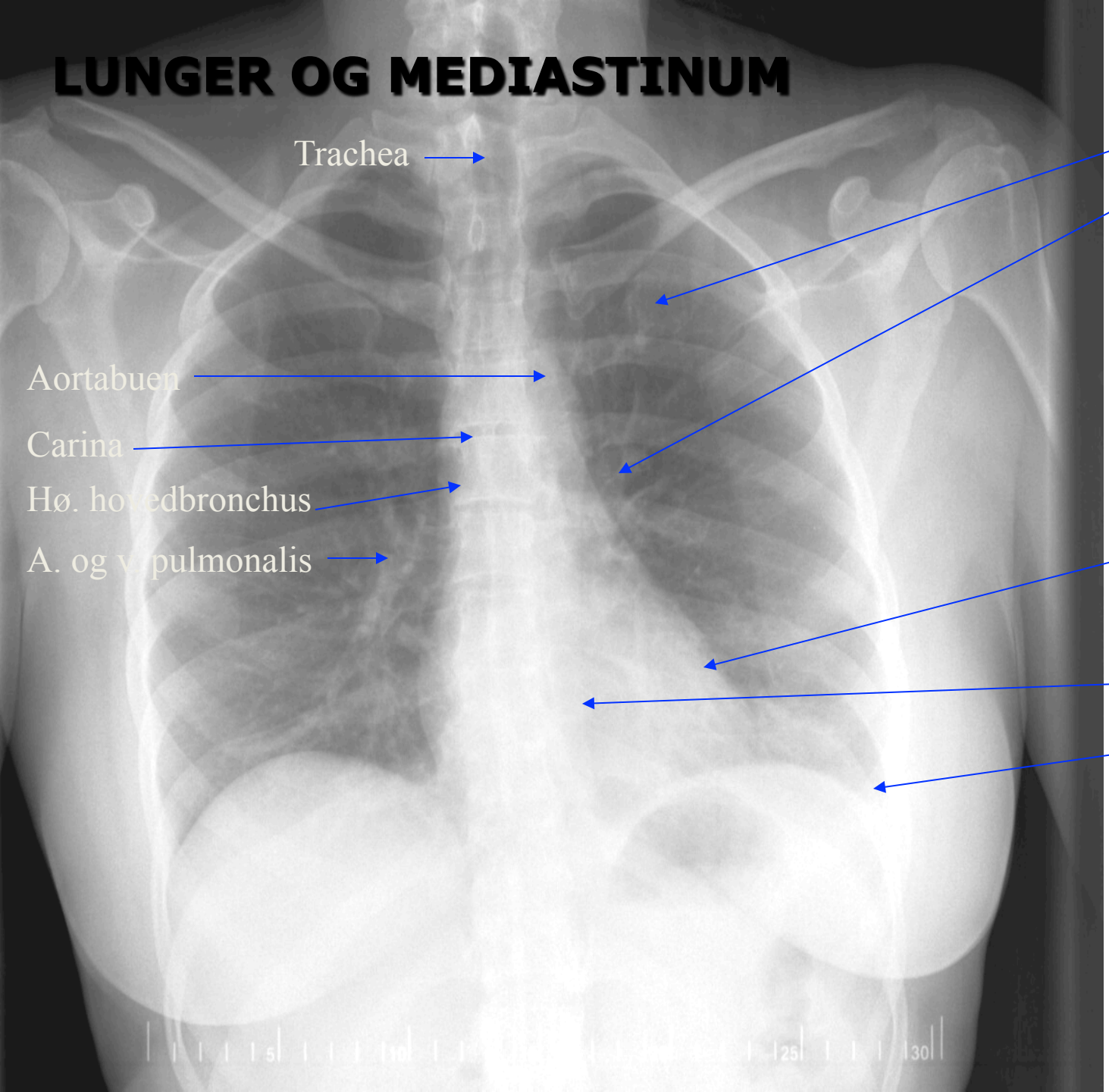

SIDEBILDE

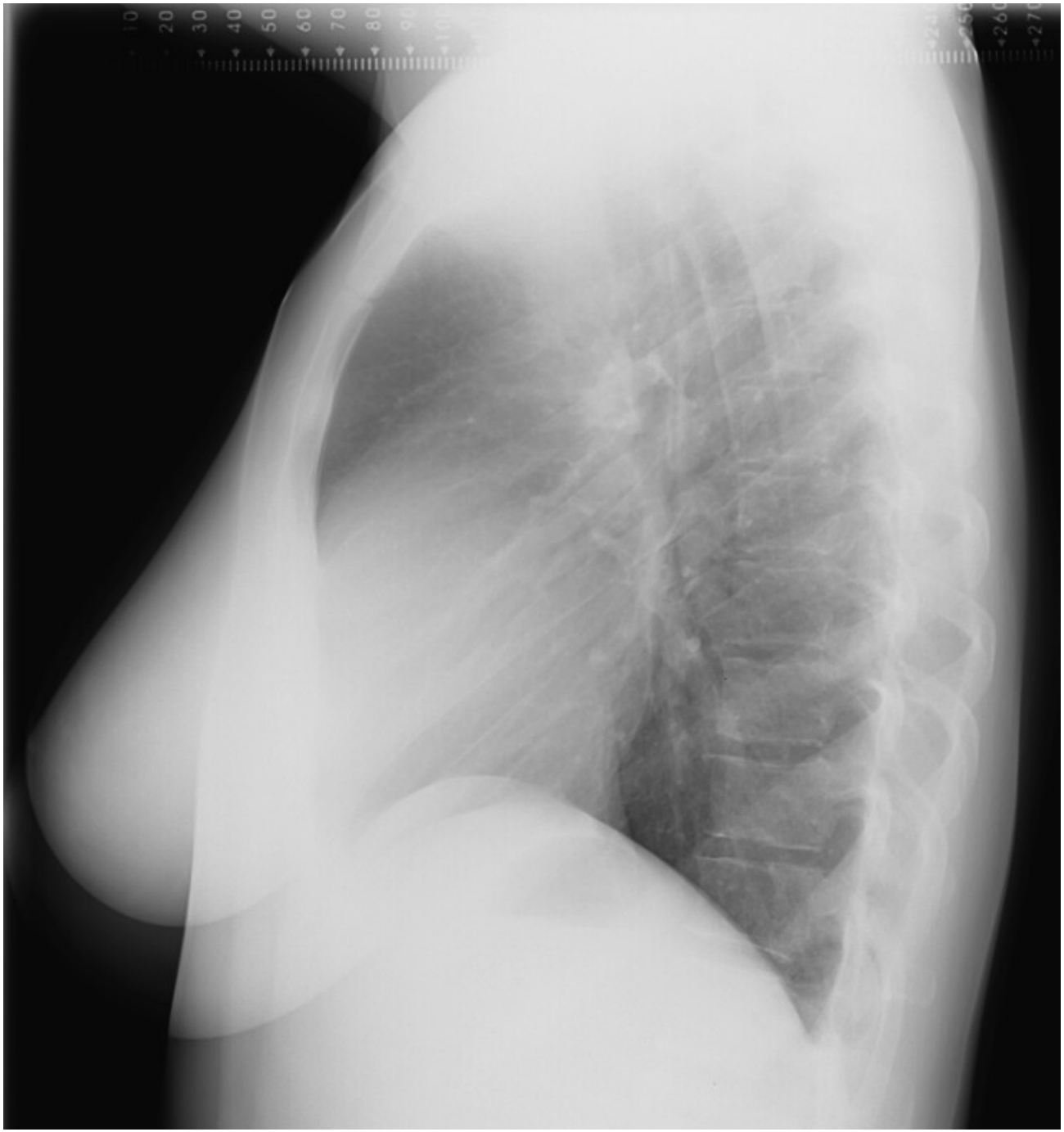

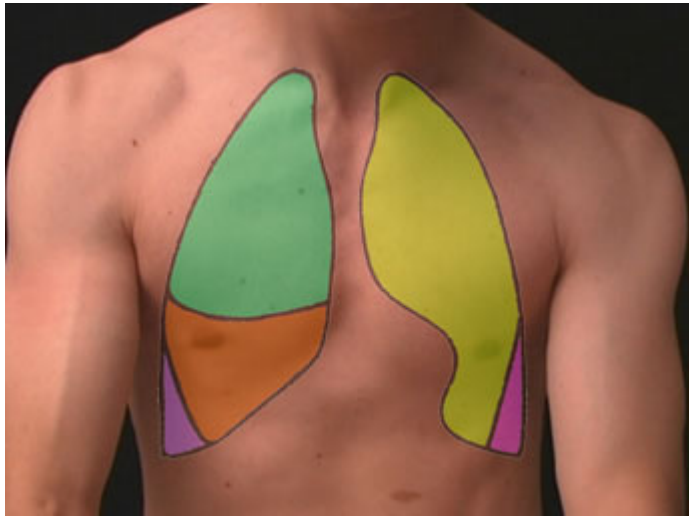

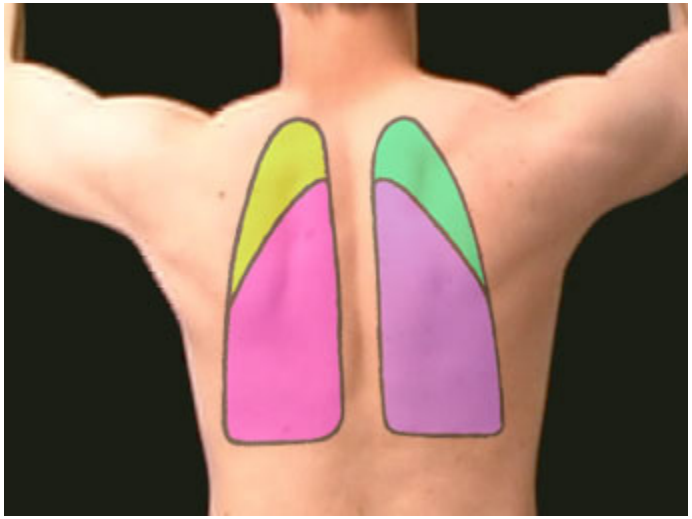

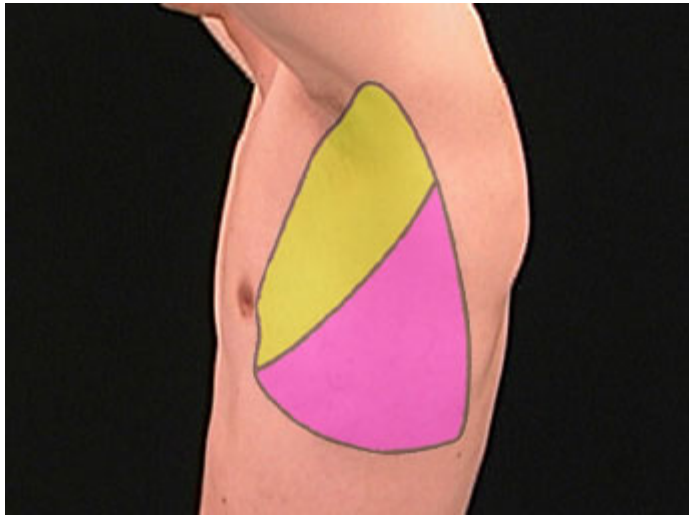

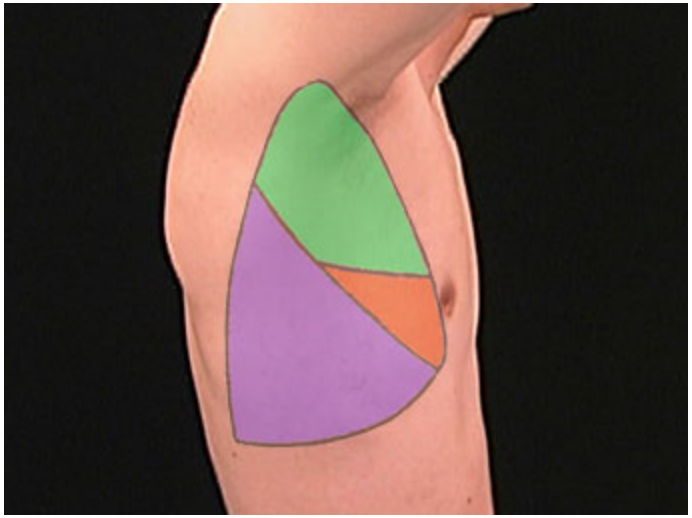

Out of clutter find simplicity.

From discord find harmony.

In the middle of difficulty lies opportunity

Albert Einstein

Normalfloskelen

Frie sinus, normal hjerteskygge og konfigurasjon av mediastinum. Klare lunger uten stuvning, atelektaser, infiltrat eller tumorsuspekte fortetninger. Ingen pneumothorax eller skjelettpatologi.

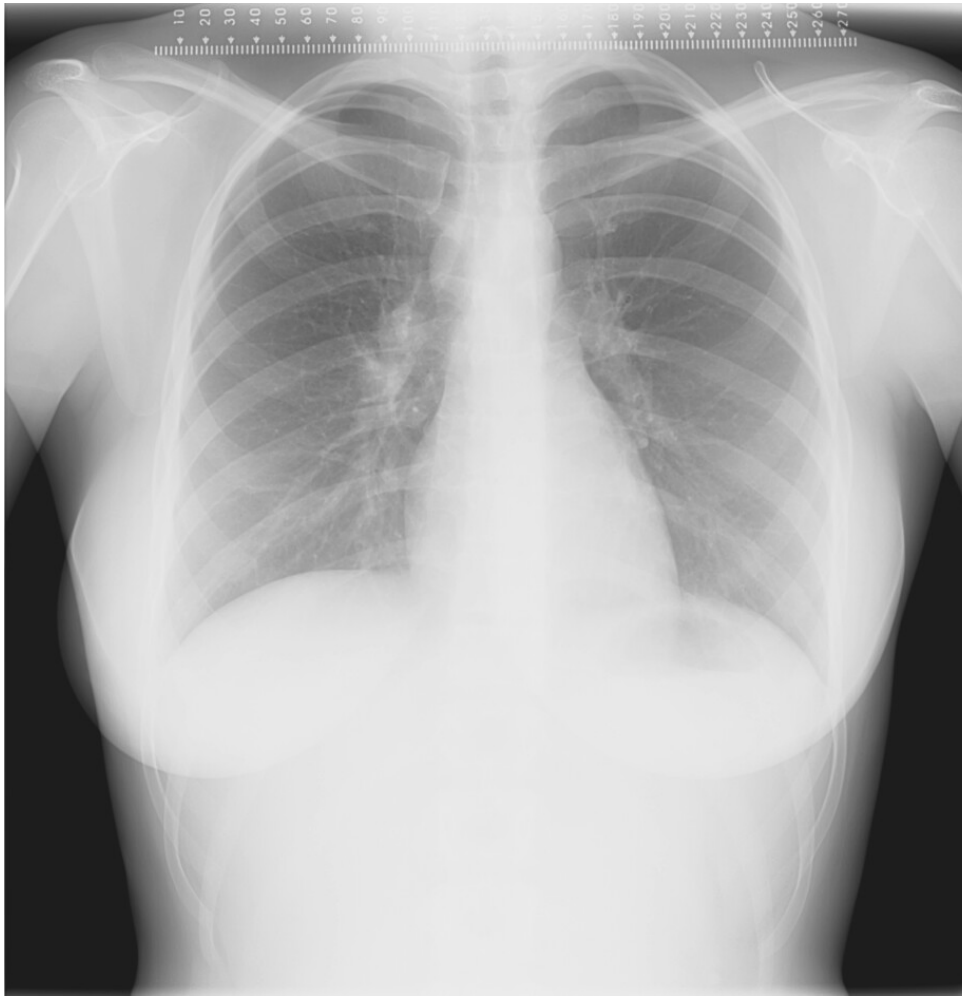

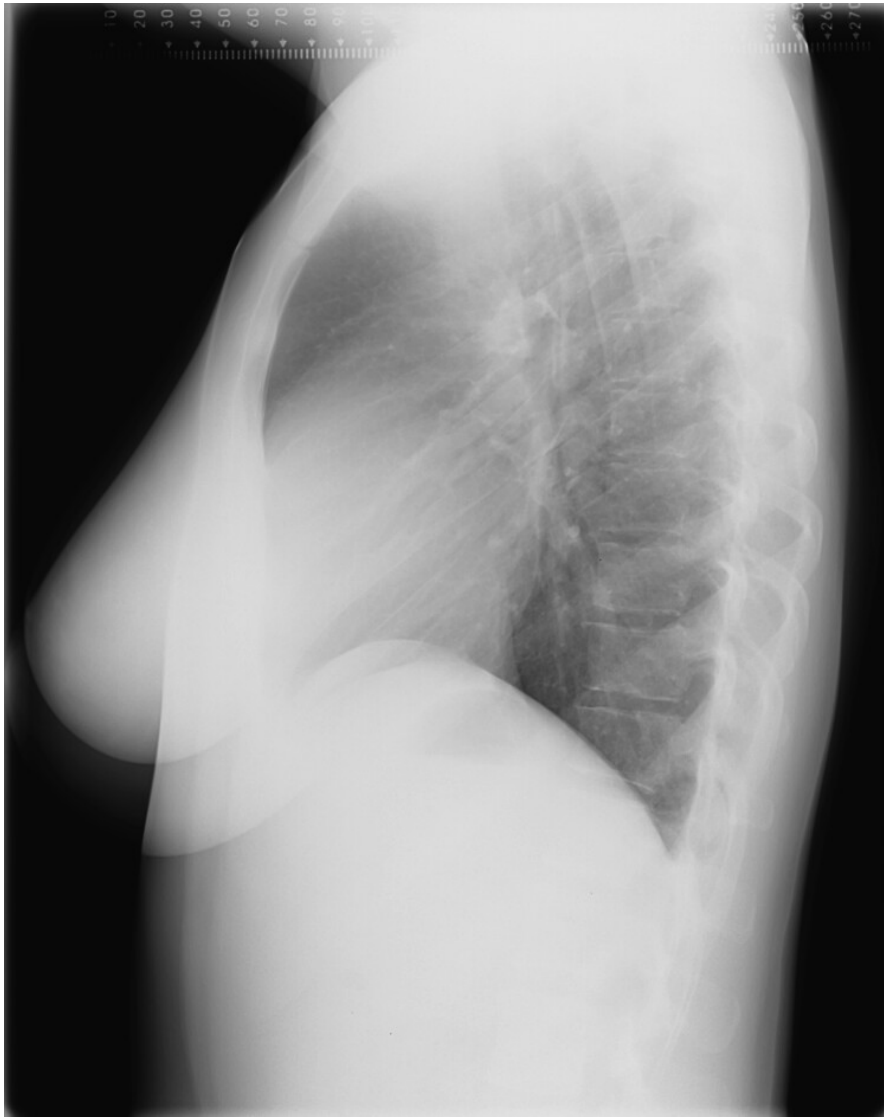

Frie sinus, normal hjerteskygge og konfigurasjon av mediastinum. Klare lunger uten stuvning, atelektaser, infiltrat eller tumorsuspekte fortetninger. Ingen pneumothorax eller skjelettpatologi.

MATAVFALL
Food waste / Biebmobázahusat
RESTAVFALL
Mixed waste / Eará bázahusat
PLAST
Plastic / Plastihkat
PAPP
REMIKS
RETURA

Pneumoni

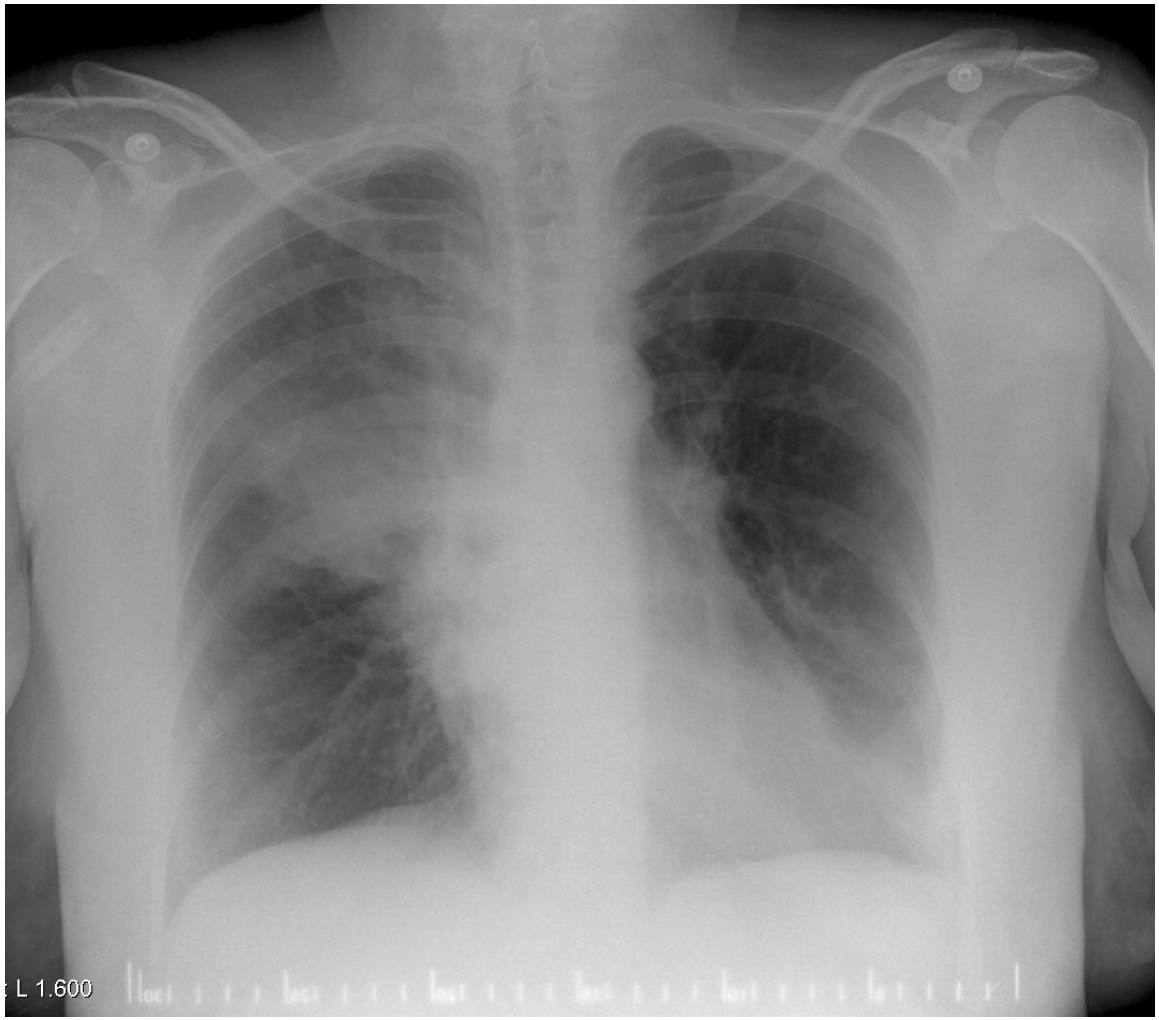

Sengebilde

Pleuravæske

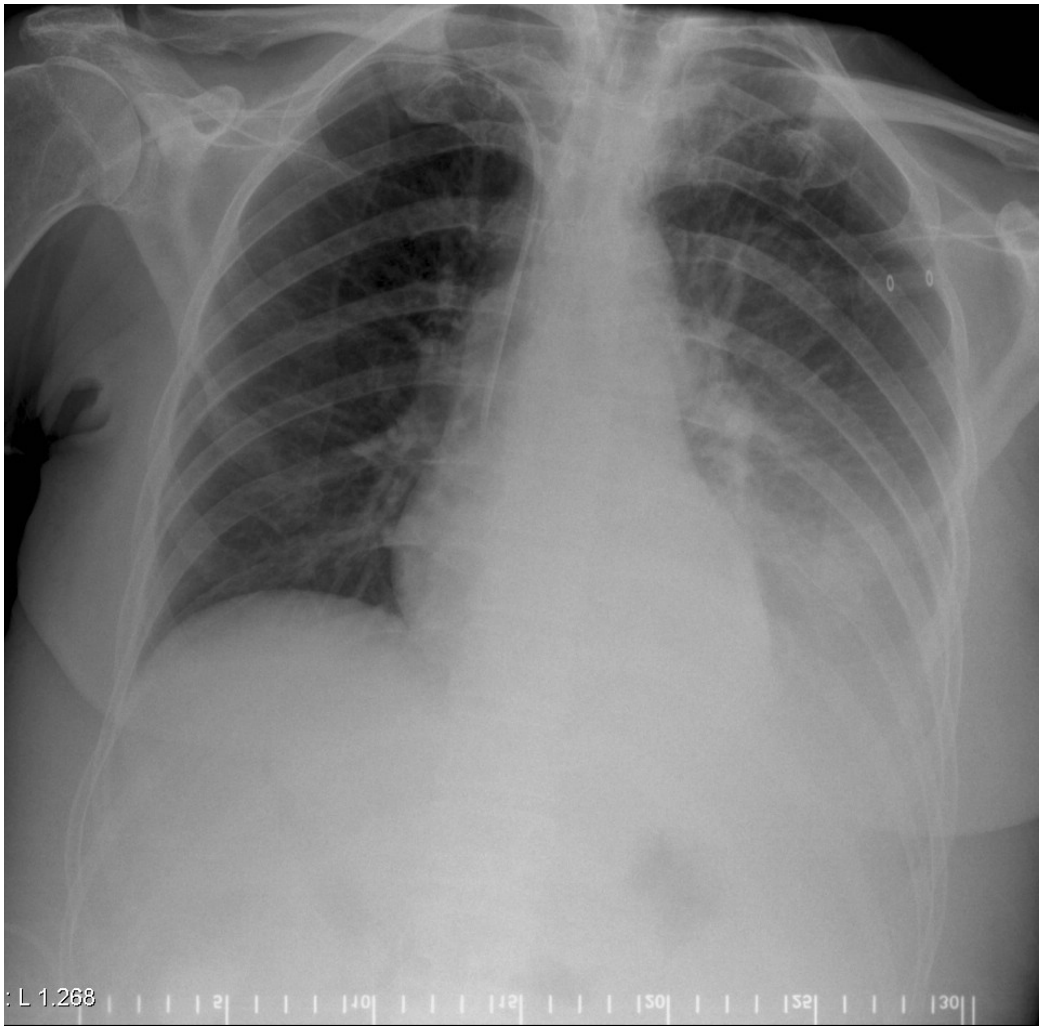

Sengebilde

Pleuravæske

- Ses best på stående bilder
- Godt synlig på CT
- Ultralyd beste undersøkelse
- Ultralydveiledet tapping ved behov

Pleuravæske

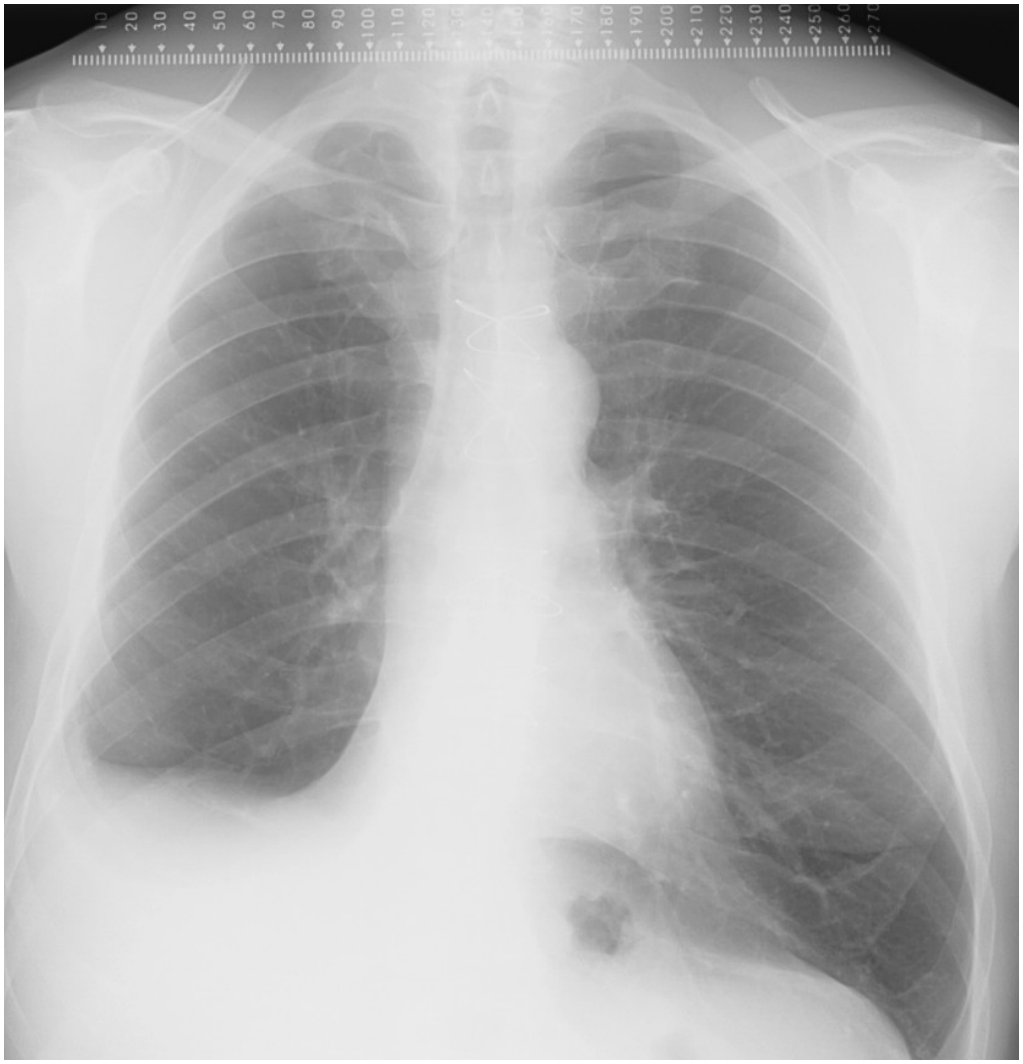

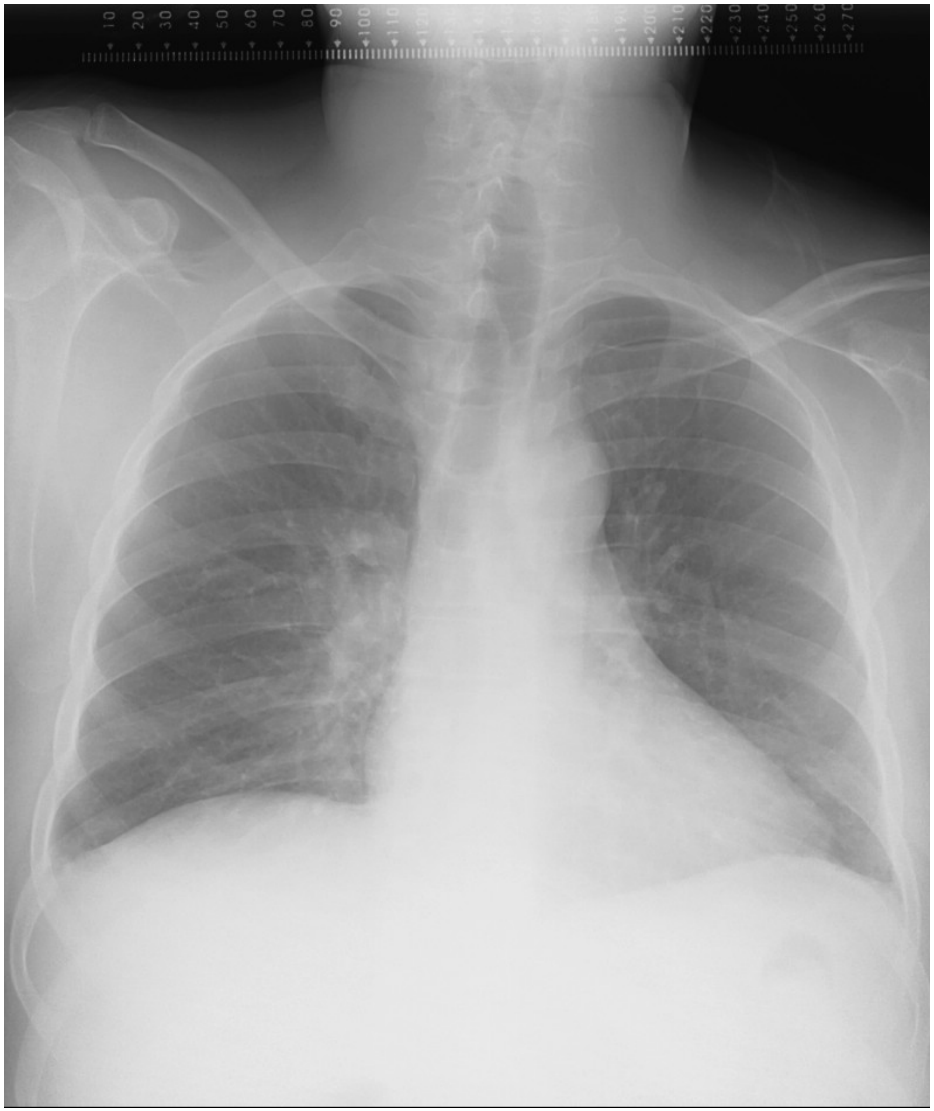

Lett avrundet sinus

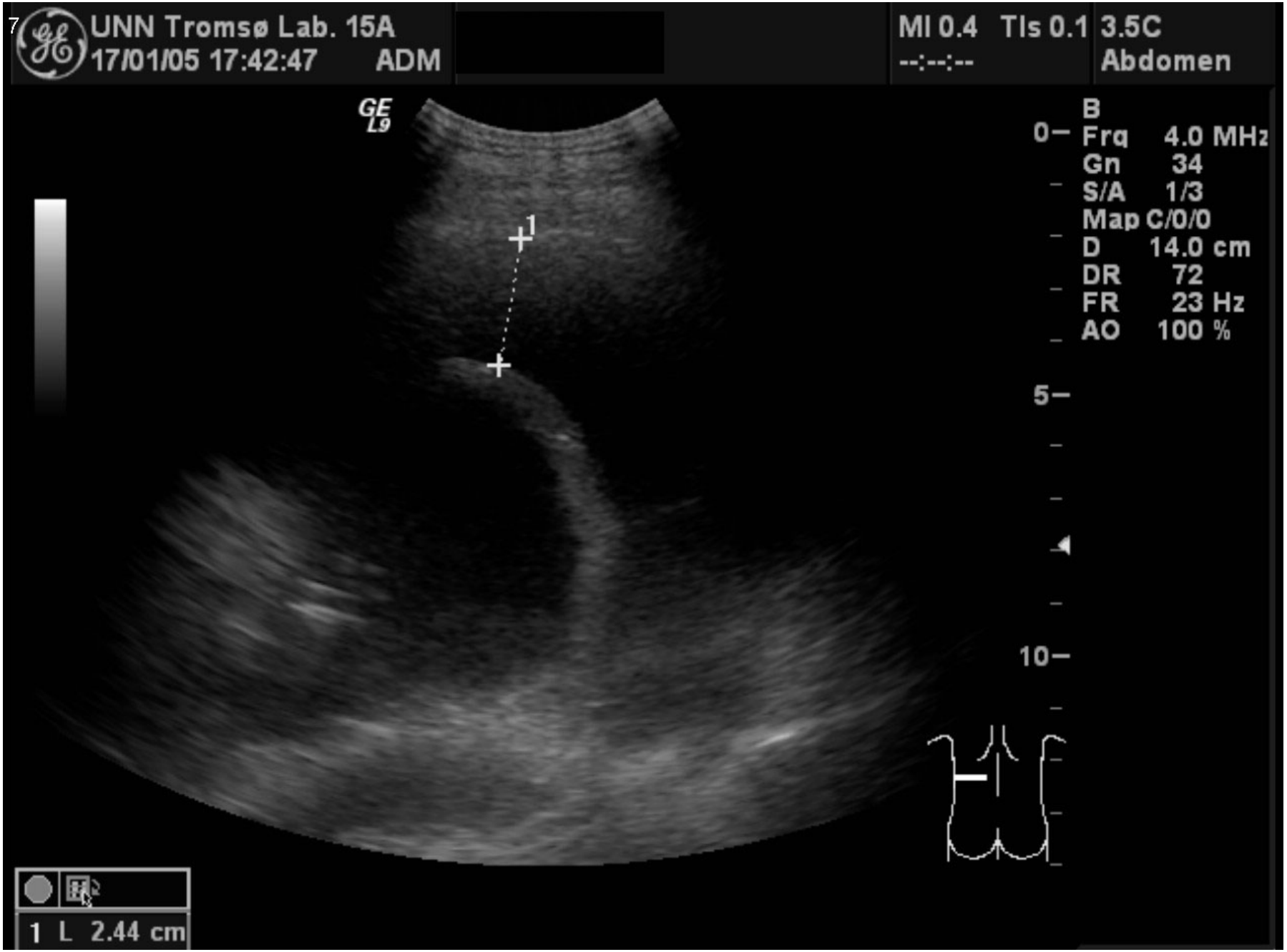
7
UNN Tromsø Lab. 15A
17/01/05 17:42:47
ADM
MI 0.4
TIs 0.1
--:--:--
3.5C
Abdomen
GE
L9
B
Frq 4.0 MHz
Gn 34
S/A 1/3
Map C/0/0
D 14.0 cm
DR 72
FR 23 Hz
AO 100 %
0
5
10
1
1 L 2.44 cm

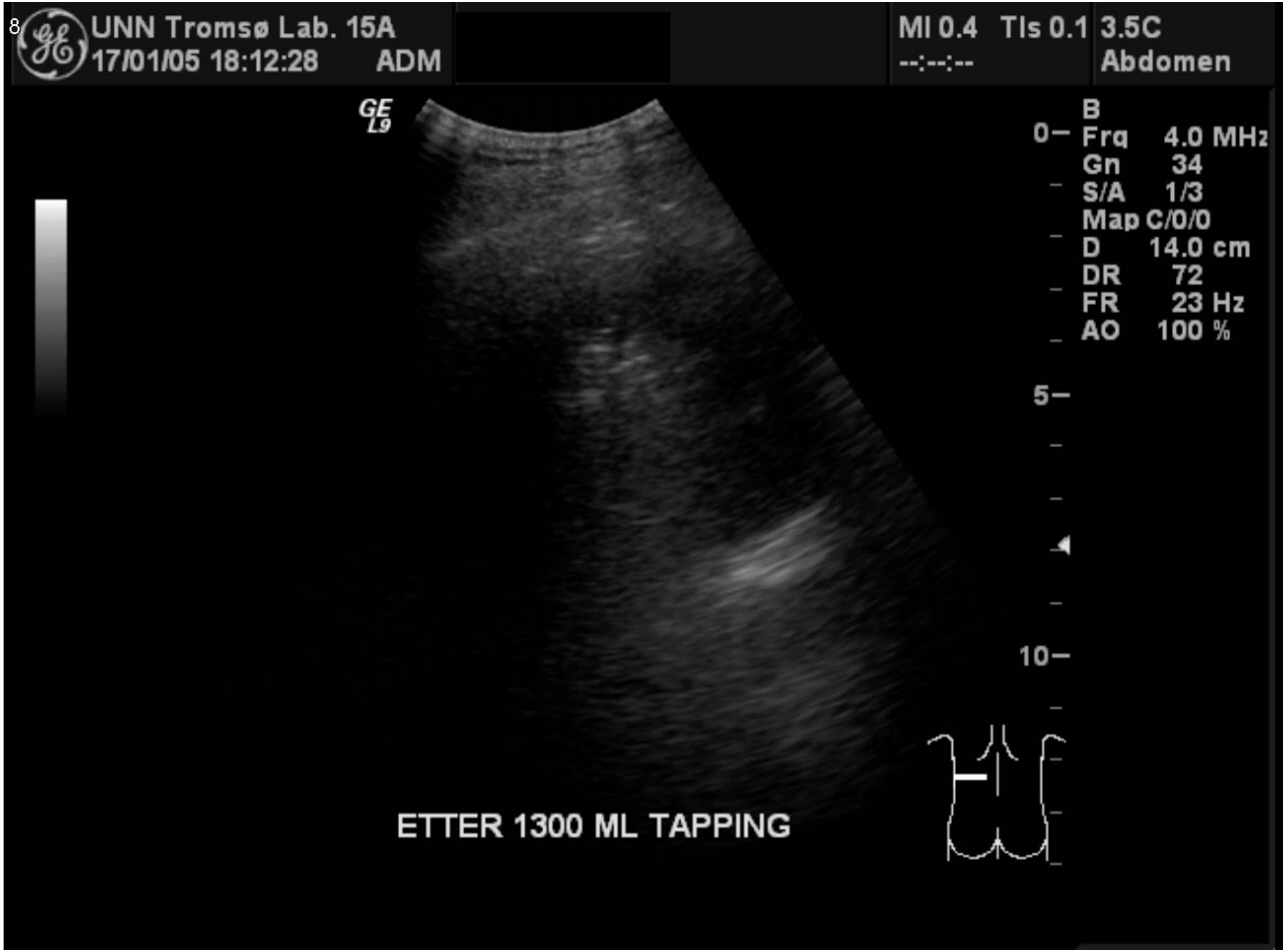
UNN Tromsø Lab. 15A
17/01/05 18:12:28 ADM
MI 0.4 TIs 0.1
--:--:--
3.5C
Abdomen
GE
L9
B
Frq 4.0 MHz
Gn 34
S/A 1/3
Map C/0/0
D 14.0 cm
DR 72
FR 23 Hz
AO 100 %
0
5
10
ETTER 1300 ML TAPPING

Stuvning

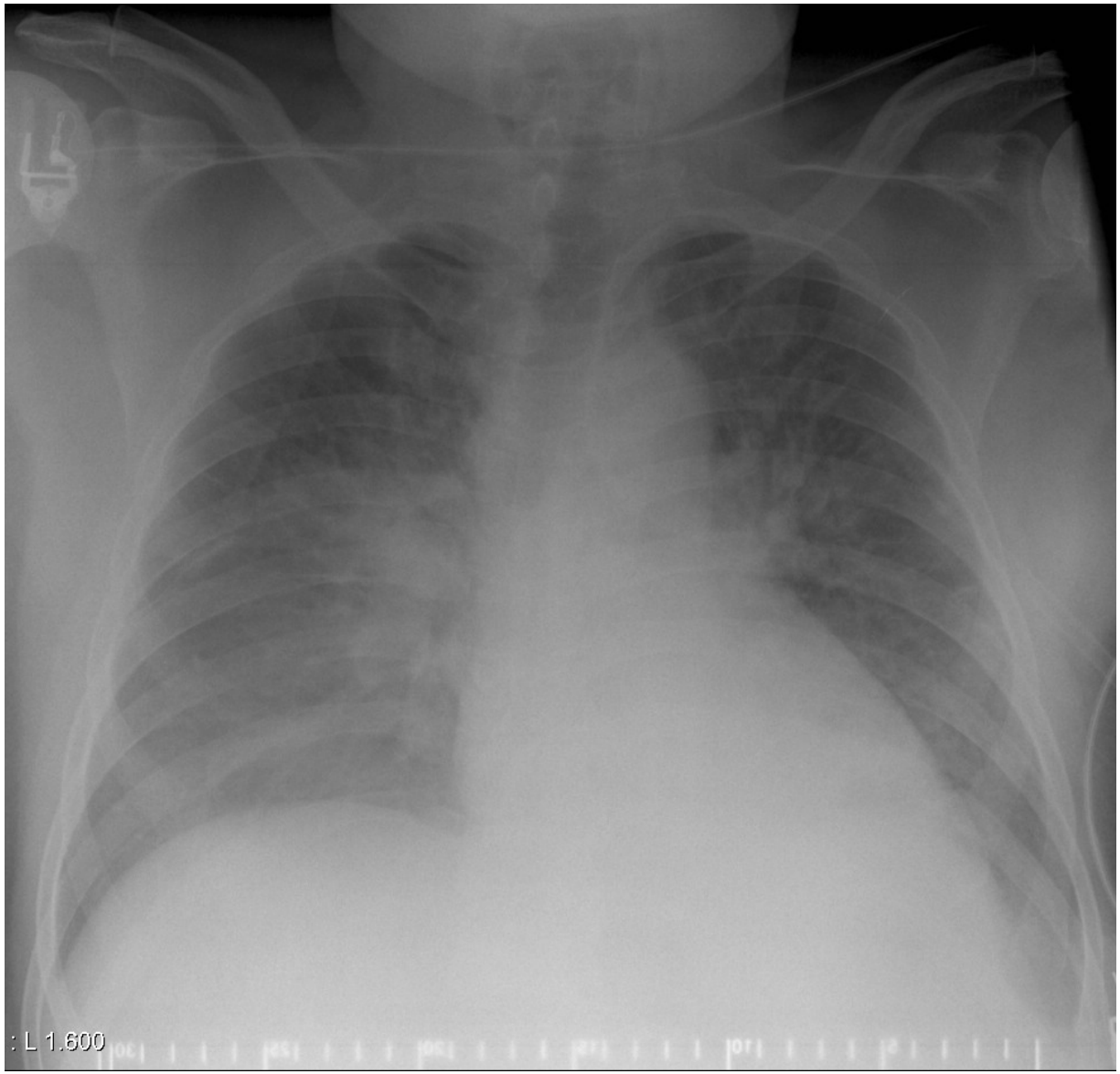

Kerley B linjer

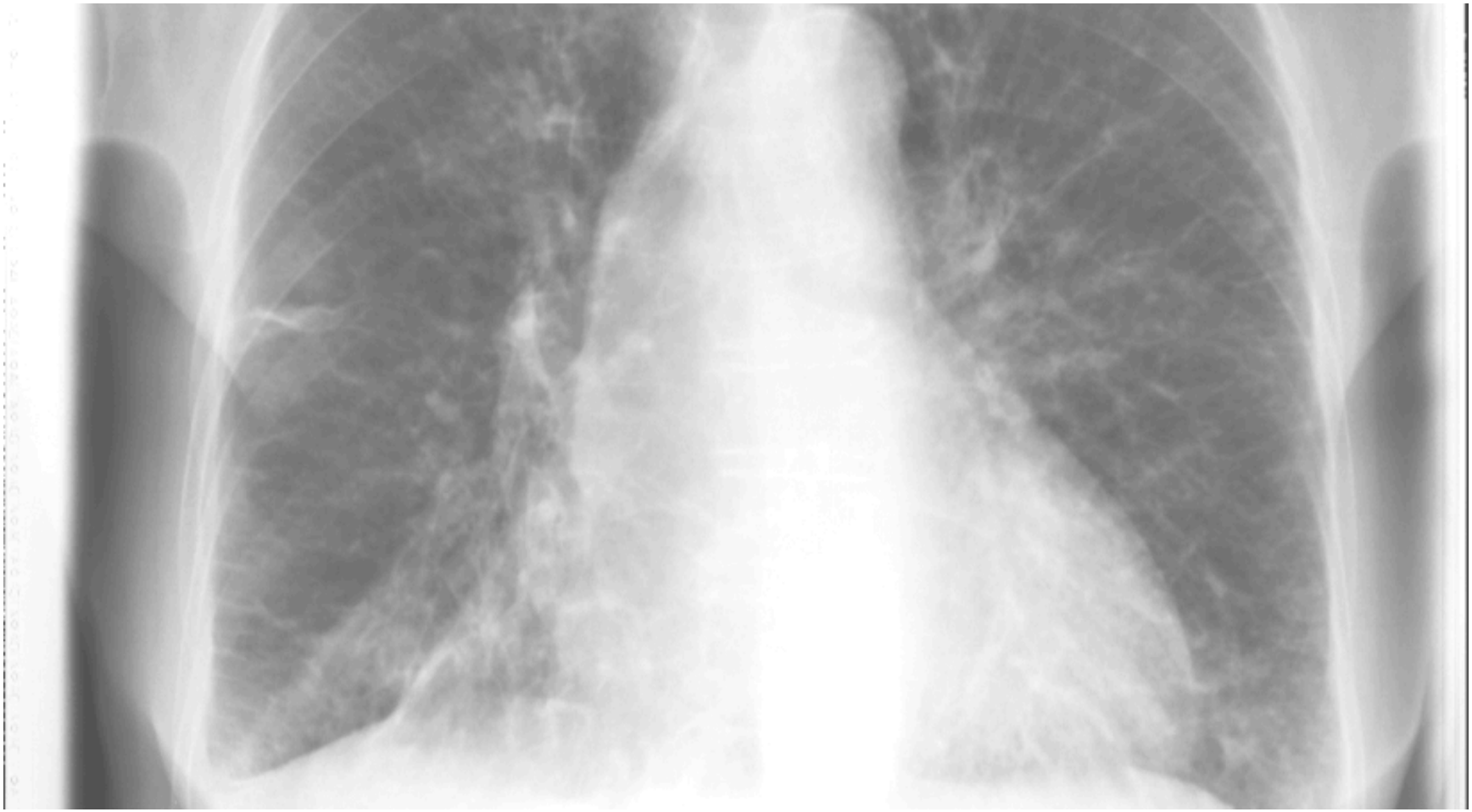

Lungeødem

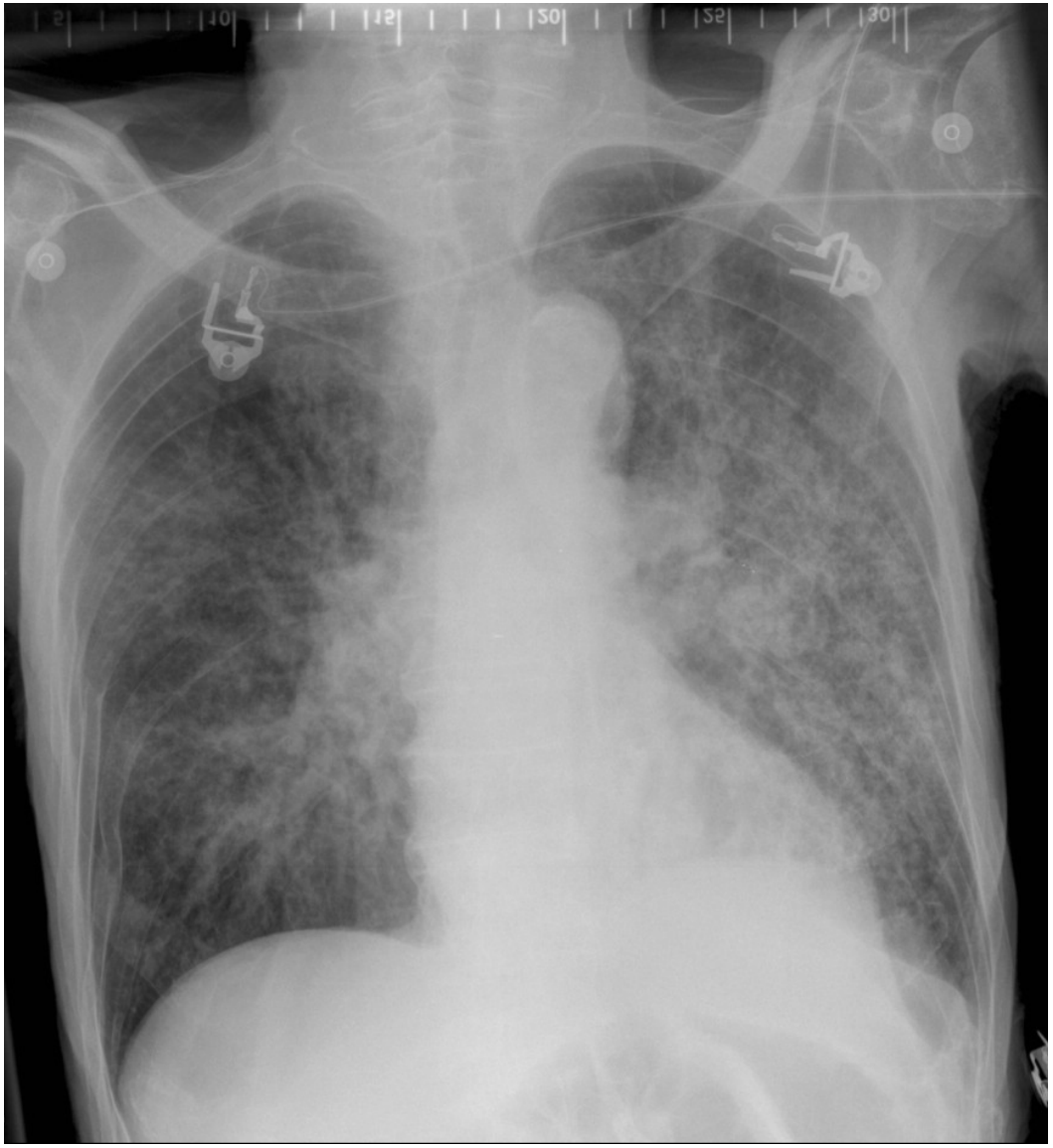

Gamle bilder til sammenlikning

Lungeemboli

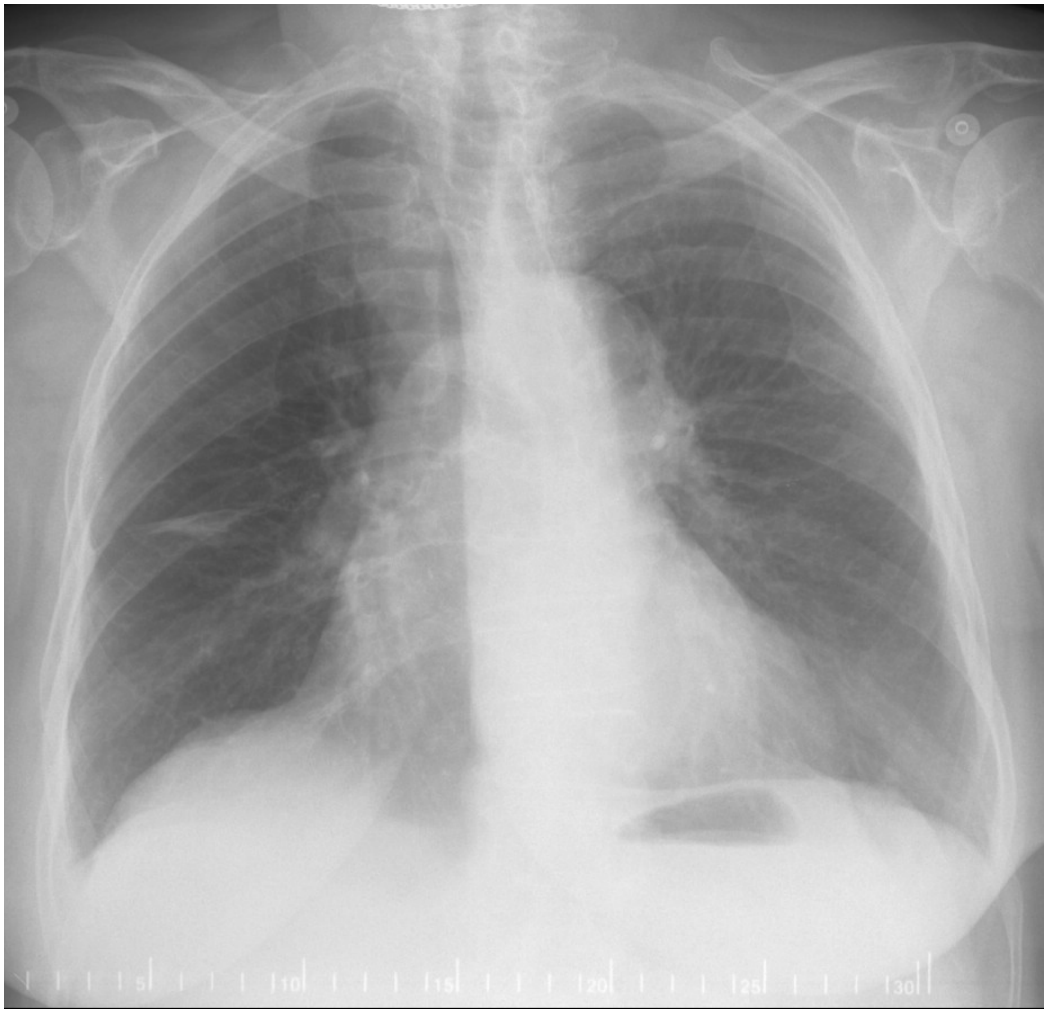

Nesten normal thorax

Lungeemboli

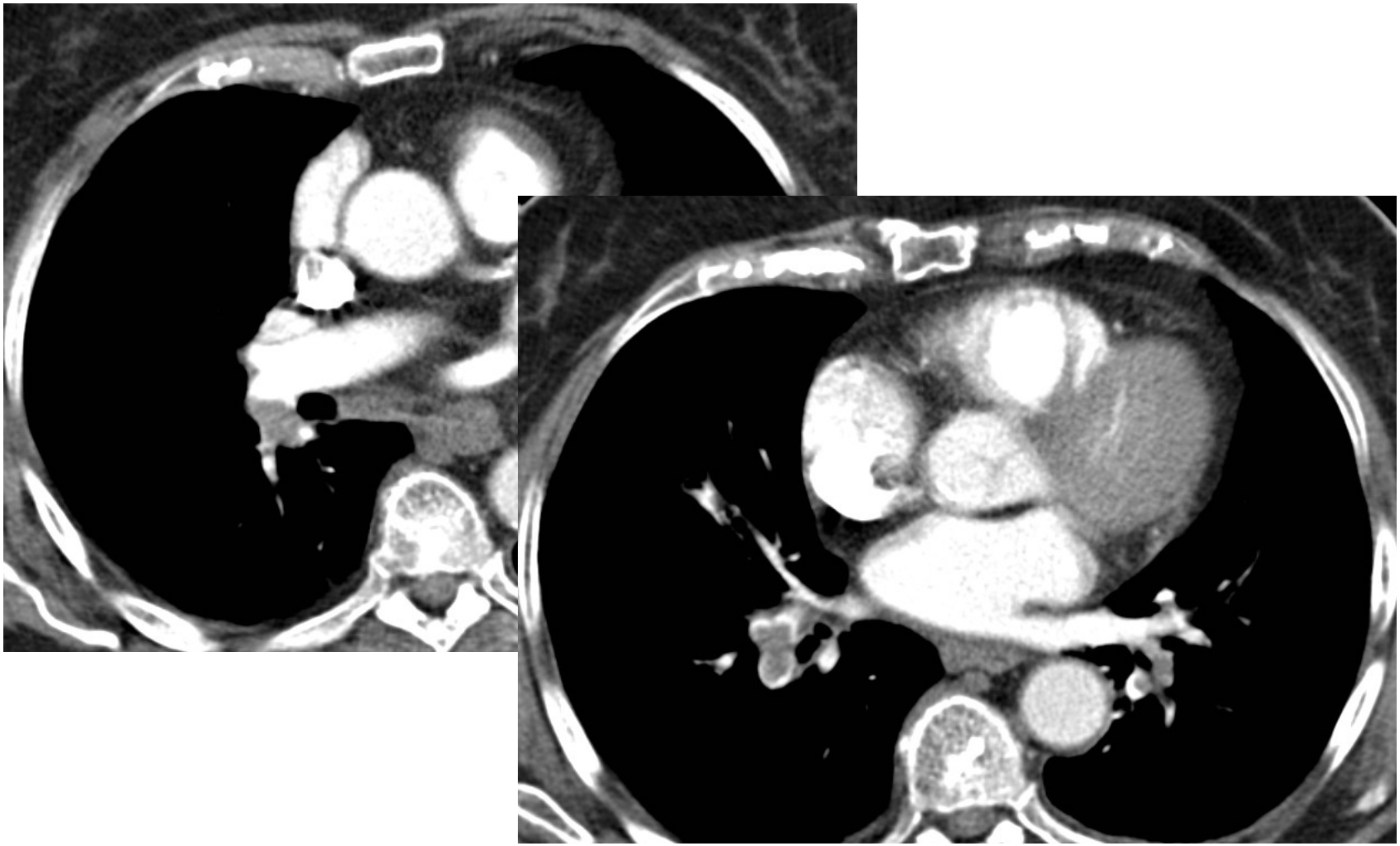

Lungeemboli

- Kan IKKE utelukkes med røntgen thorax
- CT thorax lungeemboliprotokoll
- Intravenøs kontrast
- Bolus tracking
- Påviser kontrastdefekter i lungearteriene
- Kan samtidig vise annen thoraxpatologi

Pneumothorax

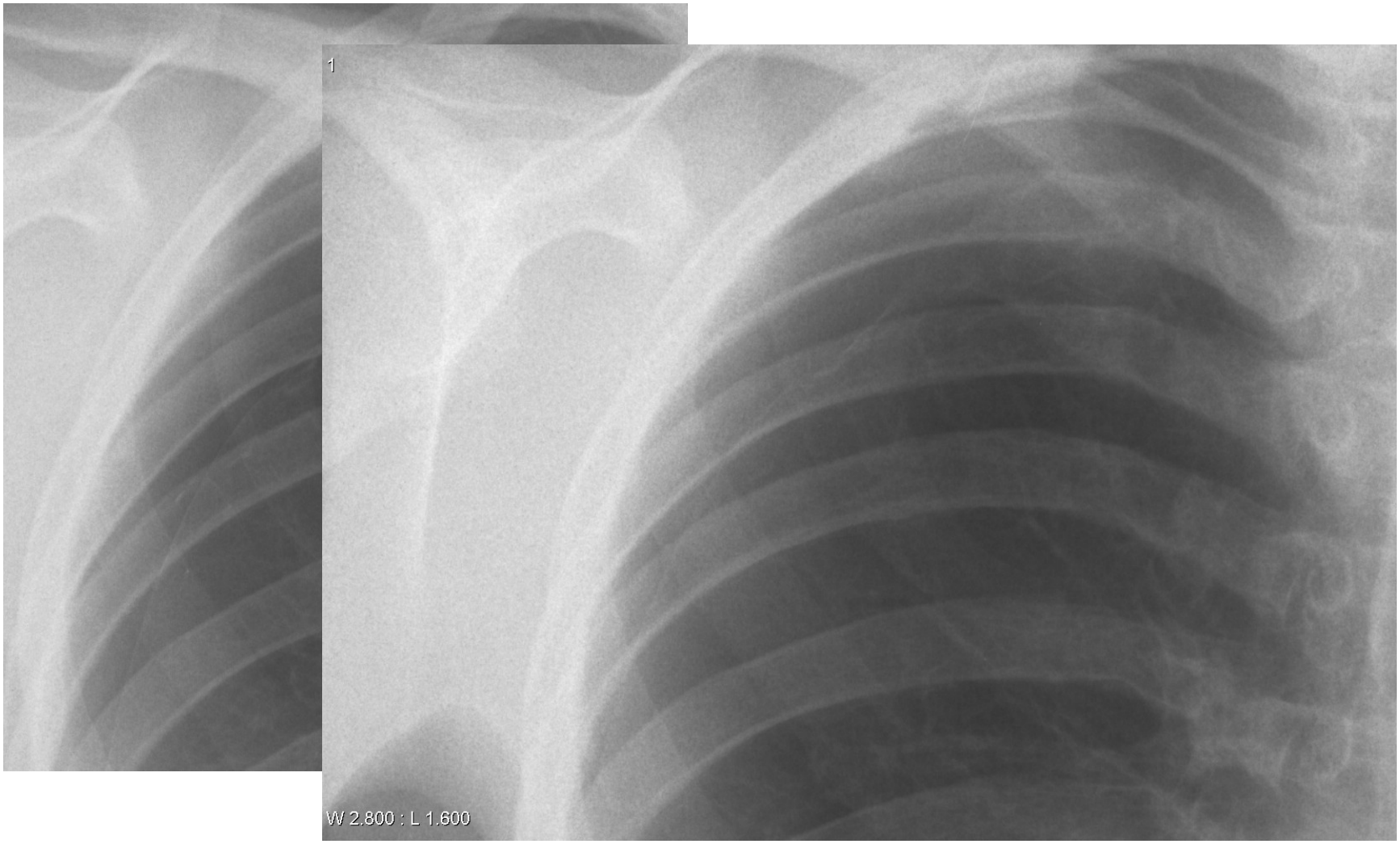

Thoraxdren

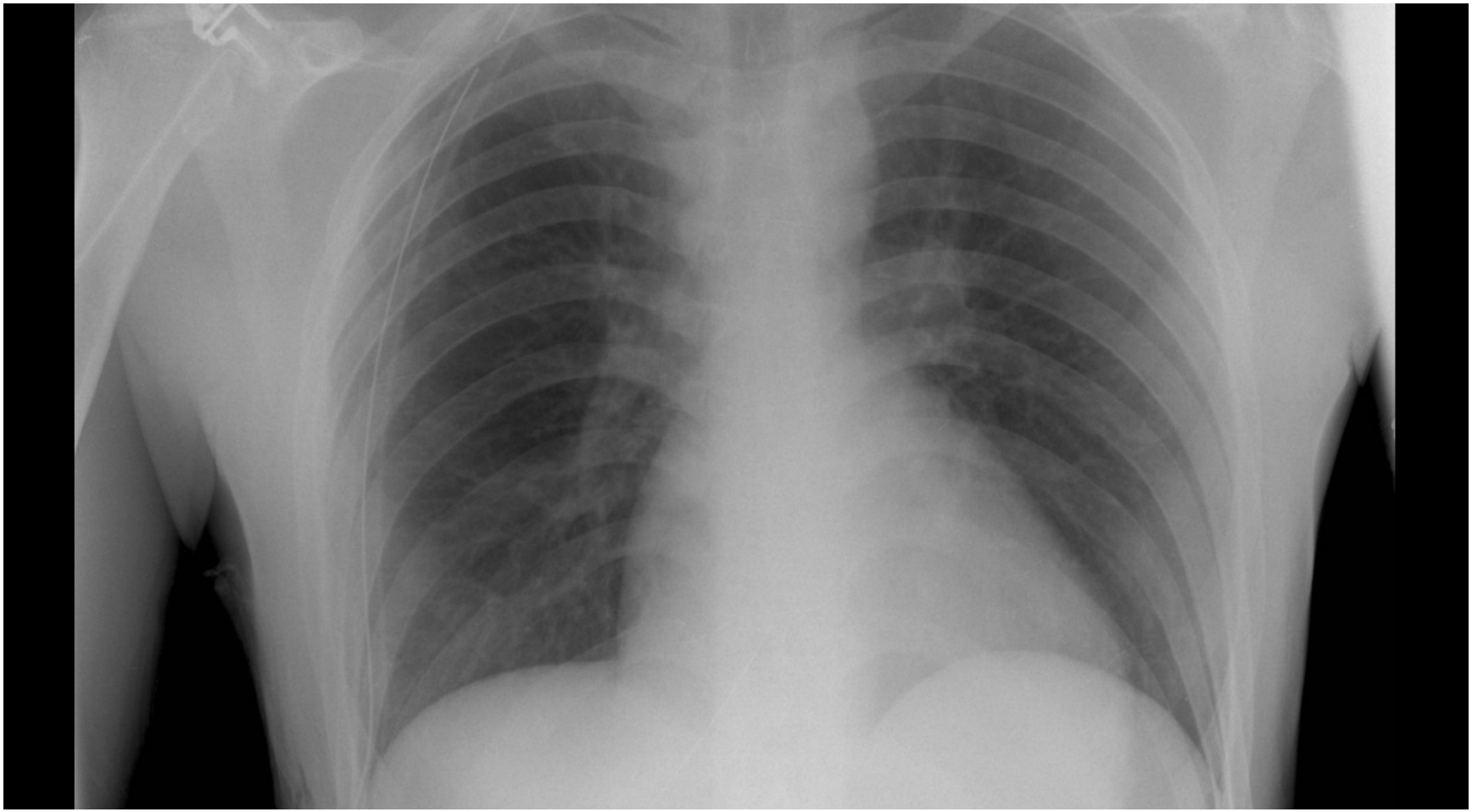

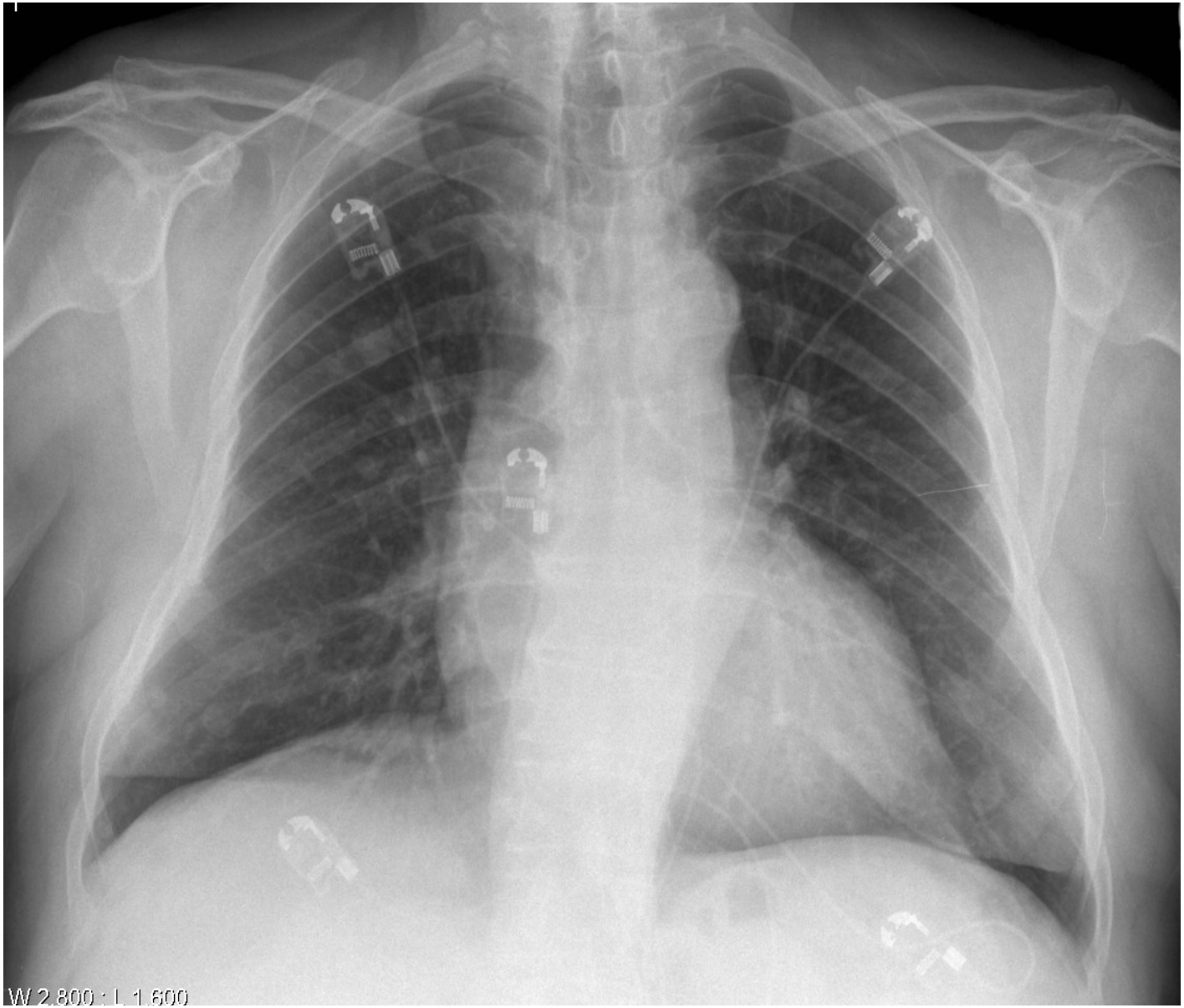

Tumorsuspekte fortetninger

Samme pasient på CT

Lungemetastaser

- Rundfortetninger
- Metastaser har større tetthet enn lungevev
- Kan være vanskelig å skille fra andre fortetninger
- Ved mistanke gjøres vanligvis CT

Skjevt opptak

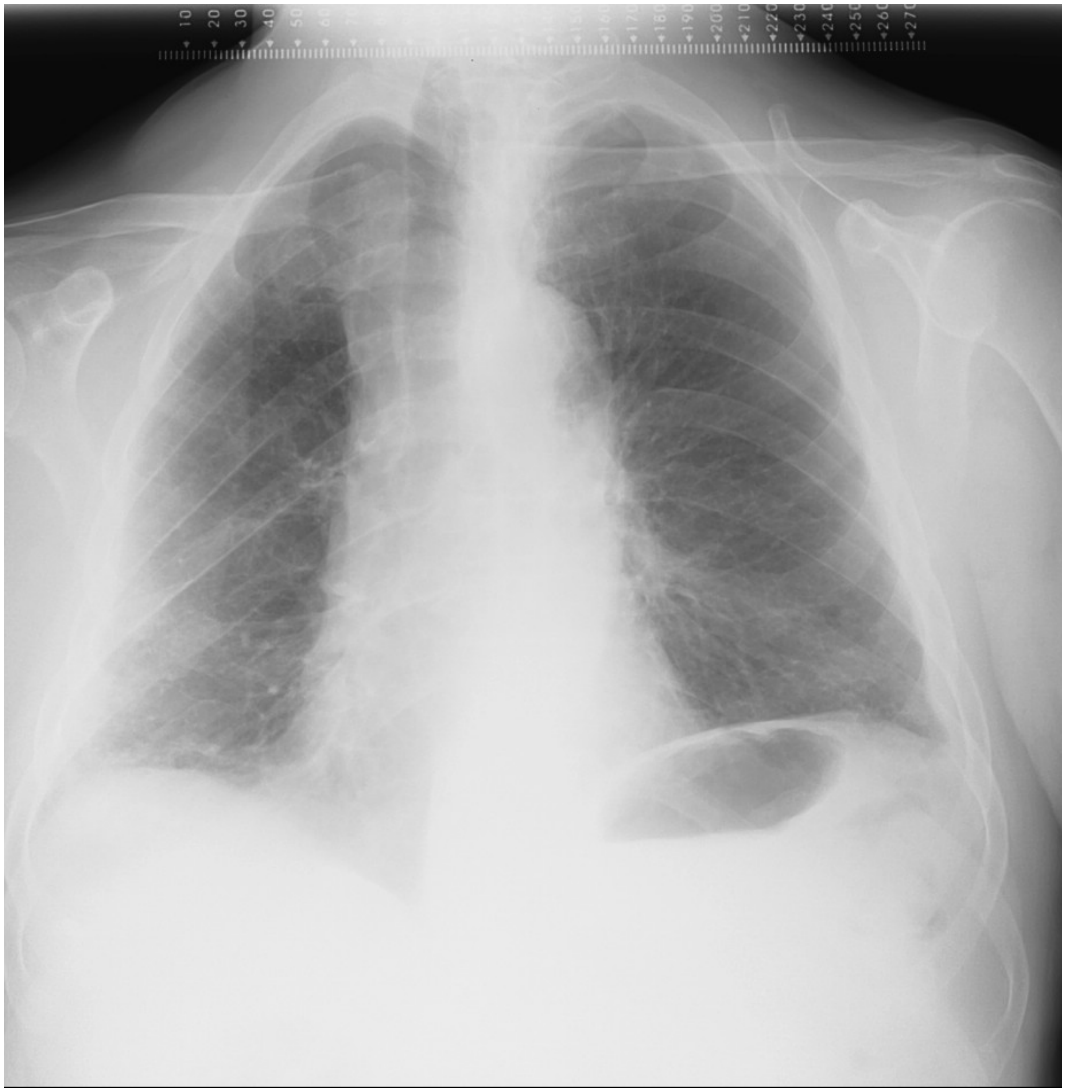

Hjertestørrelse

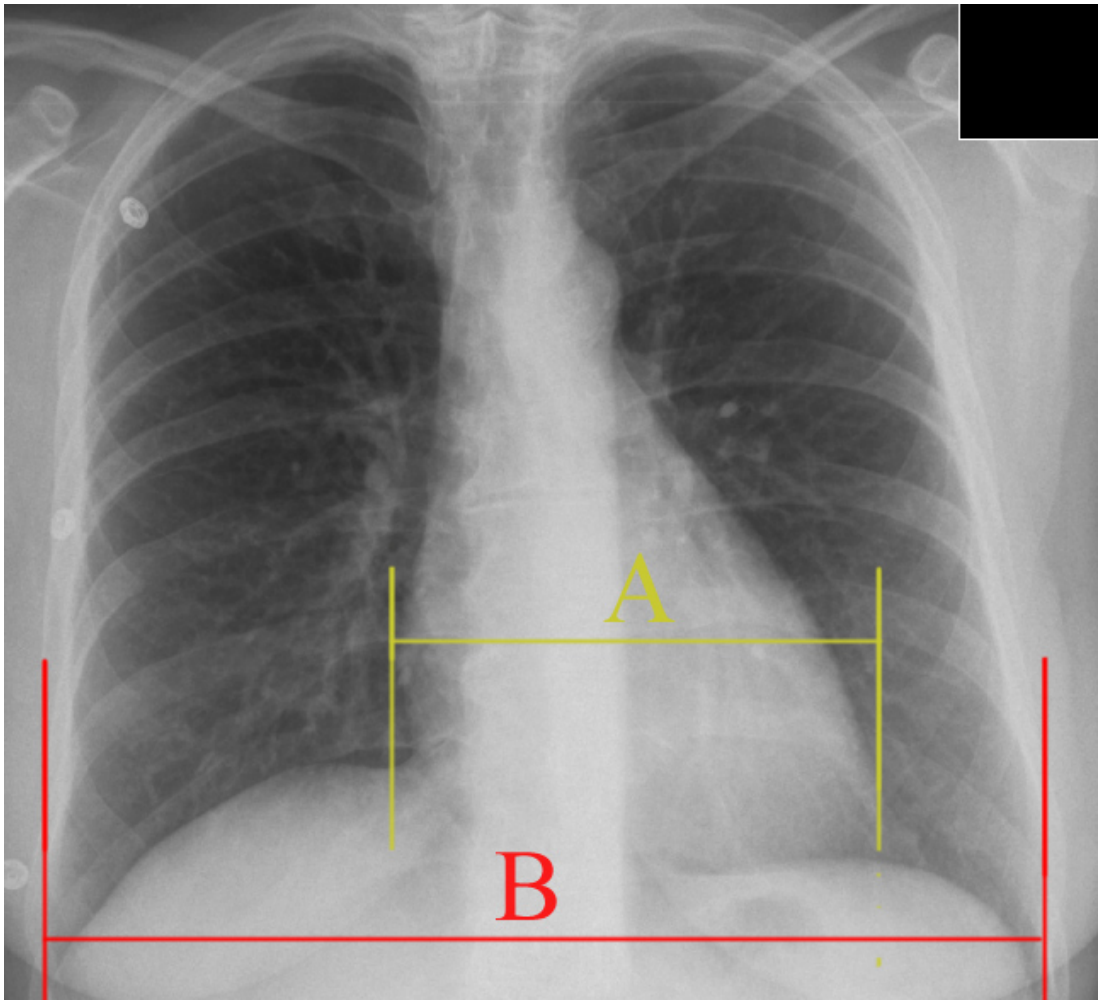

A/B < 0.5